Iran J Orthod. 2026 December; 21(2):e1512. doi:10.32592/ijorth.19.1.1512.
Published online 2026 December 1 Research Article
Case Report **Open Access**

Surgically Assisted Bone-Anchored Maxillary Protraction Combined with Maxillary Expansion in an Adolescent Patient with Class III Malocclusion: A Case Report

Alireza Ghasemzadeh [1], Erfan Shadi [2*]

[1] Assistant Professor, Department of Orthodontics, School of Dentistry, Mashhad University of Medical Sciences, Mashhad, Iran
[2] Resident, Department of Orthodontics, School of Dentistry, Mashhad University of Medical Sciences, Mashhad, Iran

***Corresponding author:** Erfan Shadi

Address: Department of Orthodontics, School of Dentistry, Park Square, Mashhad, Iran

E-mail: www.erfan.shadi20@gmail.com

Received: 2026 November 12; **Revised**: 2026 November 18; **Accepted:** 2026 November 20

Abstract

Aim
Borderline skeletal Class III malocclusion with maxillary deficiency is challenging to treat in older adolescents because the problem is not severe enough to warrant orthognathic surgery, yet conventional orthodontic treatments alone may not be sufficiently effective. This case report presents the treatment of a patient utilizing bone-anchored maxillary protraction (BAMP) combined with surgical modification to reduce maxillary resistance structures.

Case Presentation
A 15-year-old female patient presented with bilateral Class III molar and canine relationships, accompanied by anterior and posterior crossbites. Pretreatment cephalometric analysis demonstrated a skeletal Class III pattern, with an SNA angle of 78.2°, an SNB angle of 80.6°, an ANB angle of −2.4°, and a Wits appraisal of −7.5 mm.

Intervention
Initially, four L-shaped miniplates were secured to the maxillary zygomatic buttresses and the mandibular canine regions. Bilateral cortical Le Fort I osteotomies were subsequently performed without down-fracture or repositioning of the maxilla. Class III elastics were worn full-time for 6 months, followed by nighttime wear for an additional 7 months. Concurrently, maxillary expansion was initiated and activated once daily by the patient. After completion of the expansion phase, comprehensive fixed orthodontic treatment was undertaken to achieve dental alignment and leveling, correct the anterior and posterior crossbites, and establish optimal final occlusal relationships.

Results
Treatment resulted in bilateral Class I molar and canine relationships, correction of the anterior crossbite, and establishment of a 1-mm overjet and overbite. Cephalometric evaluation demonstrated modest skeletal changes, including increases in SNA by 1.3°, SNB by 0.6°, ANB by 0.7°, and Wits appraisal by 6.3 mm, along with a 1.7° reduction in FMA. Dentoalveolar changes included a 1.7° decrease in the U1–SN angle and a 2.7° increase in the IMPA. A slight improvement in the facial profile was also observed.

Conclusion
In this adolescent patient, the combined protocol of bilateral cortical Le Fort I osteotomies, four-miniplate BAMP, maxillary expansion, and fixed orthodontics successfully corrected crossbites and achieved an acceptable occlusion with modest skeletal improvement. While offering an alternative for patients declining orthognathic surgery, further controlled studies with long-term follow-up are needed to validate its efficacy and stability.

Keywords: Skeletal Class III, Bone-Anchored Maxillary Protraction, Le Fort I Osteotomy

Copyright © 2026, Author(s). This is an open-access article distributed under the terms of the Creative Commons Attribution-NonCommercial 4.0 International License (http://creativecommons.org/licenses/by-nc/4.0/) which permits copy and redistribute the material just in noncommercial usages, provided the original work is properly cited.

Background

Skeletal Class III malocclusion is a complex dentofacial condition that may result from maxillary deficiency, mandibular prognathism, or both. Maxillary hypoplasia is a common contributing factor and may be associated with anterior crossbite, transverse maxillary deficiency, and compromised facial esthetics(1).

Treatment is particularly challenging in adolescents approaching the end of their growth period, in whom the potential for conventional orthopedic correction may be limited(1).

Conventional maxillary protraction using a facemask can produce favorable skeletal changes but may also be associated with dentoalveolar compensation, particularly maxillary incisor proclination(2).

A systematic review and meta-analysis comparing dental-anchored and skeletally anchored facemask protocols found greater maxillary incisor proclination with dental anchorage (3). This has led to the introduction of maxillary protraction treatments using skeletal anchorage (1,2).

Bone-anchored maxillary protraction (BAMP) was introduced as an intraoral alternative to facemask treatment. The conventional protocol involves four miniplates placed in the maxillary infrazygomatic buttress and mandibular symphyseal regions, connected by intermaxillary Class III elastics. De Clerck et al. reported favorable maxillary and circummaxillary changes following this approach (2).

They also showed this approach offers a promising alternative to restrain mandibular growth for Class III patients with a component of mandibular prognathism or to compensate for maxillary deficiency in patients with hypoplasia of the midfaces(4).

It has been also reported that BAMP produced significant improvements in skeletal relationships and overjet compared with an untreated control group. At the 3-year follow-up, the perceived need for orthognathic surgery was also lower in the BAMP group (5).

Moreover, It was found that outcomes varied according to the bone-borne protraction protocol. Hybrid Hyrax with mandibular bone anchorage showed greater maxillary advancement than conventional BAMP, while bone-anchored approaches generally produced fewer dentoalveolar side effects than facemask-based protocols (8).

In a longitudinal study, Esposito et al. found that BAMP improved sagittal skeletal measurements. Although it did not significantly reduce the overall frequency of subsequent orthognathic surgery, BAMP-treated patients managed with orthodontic camouflage had a lower extraction rate than untreated controls (7).

Subsequent comparative studies have demonstrated differences in skeletal and dentoalveolar responses between skeletal anchorage-based protocols (8,9). However, the extent and clinical significance of the skeletal changes induced by BAMP remain under debate. Systematic reviews have highlighted limited evidence for substantial maxillary advancement, methodological limitations in the available studies, and a lack of long-term follow-up (10–12).

Surgical modification of resistance structures in the maxilla has also been investigated to facilitate protraction. Yilmaz et al. evaluated corticotomy-assisted maxillary protraction using skeletal anchorage and Class III elastics, incorporating an incomplete Le Fort I osteotomy to reduce resistance to maxillary displacement (13). This approach supports combining skeletal anchorage with surgical weakening of selected maxillary resistance structures.

Transverse maxillary deficiency poses an additional challenge in patients with skeletal Class III malocclusion. Elnagar et al. reported that transverse deficiency did not improve spontaneously after miniplate-anchored maxillary protraction, supporting the need for a separate expansion strategy when constriction is present (14). Although expansion has been incorporated into various maxillary protraction protocols, evidence of its additional skeletal benefits remains inconsistent and may depend on the protocol, skeletal maturity, and anchorage design (15,16).

This case report describes an adolescent patient with skeletal Class III malocclusion and maxillary transverse deficiency treated with bilateral Le Fort I osteotomies without down-fracture or maxillary repositioning, four-miniplate BAMP, and concurrent tooth-borne maxillary expansion, followed by comprehensive fixed orthodontic treatment.

Case Presentation

A 15-year-and-10-month-old female patient presented to the Department of Orthodontics of Mashhad University of Medical Sciences, with a chief complaint of irregular dentition and poor facial esthetics. The patient’s history showed no previous orthodontic treatment. Her medical history was unremarkable except for a previous

adenoidectomy. No family history of Class III malocclusion was reported.

Although menarche occurred at age 14, cervical vertebral maturation (CVM) staging could not be reliably assessed on the lateral cephalogram because the thyroid collar obscured the cervical vertebrae, preventing their complete visualization.

Extraoral examination revealed a relatively straight, anteriorly divergent facial profile, mild deficiency in the cheek and infraorbital regions. The lips appeared retrusive in relation to the E-line, and the nasolabial angle was increased.

Intraoral examination revealed bilateral Class III molar and canine relationships. The overjet= -1 mm and overbite=0 mm. Bilateral posterior crossbite was also present, consistent with maxillary transverse deficiency. Moderate crowding was observed in the maxillary anterior segment, whereas mandibular anterior crowding was mild. Both maxillary and mandibular dental midlines were deviated to the right relative to the facial skeletal midline (Figure 1).

Pretreatment lateral cephalometric analysis showed an SNA angle of 78.2°, an SNB angle of 80.6°, and an ANB angle of −2.4°. The Wits appraisal was −7.5 mm, indicating a Class III skeletal relationship. The FMA was 25.9°. The maxillary incisor inclination (U1-SN) was 104.5°, and the mandibular incisor inclination (IMPA) was 80.6° (Figure 2).

The pretreatment diagnosis was skeletal Class III malocclusion associated with maxillary transverse deficiency, moderate maxillary anterior crowding, and mild mandibular anterior crowding.



Figure 1: Pretreatment records: extraoral and intraoral photographs.

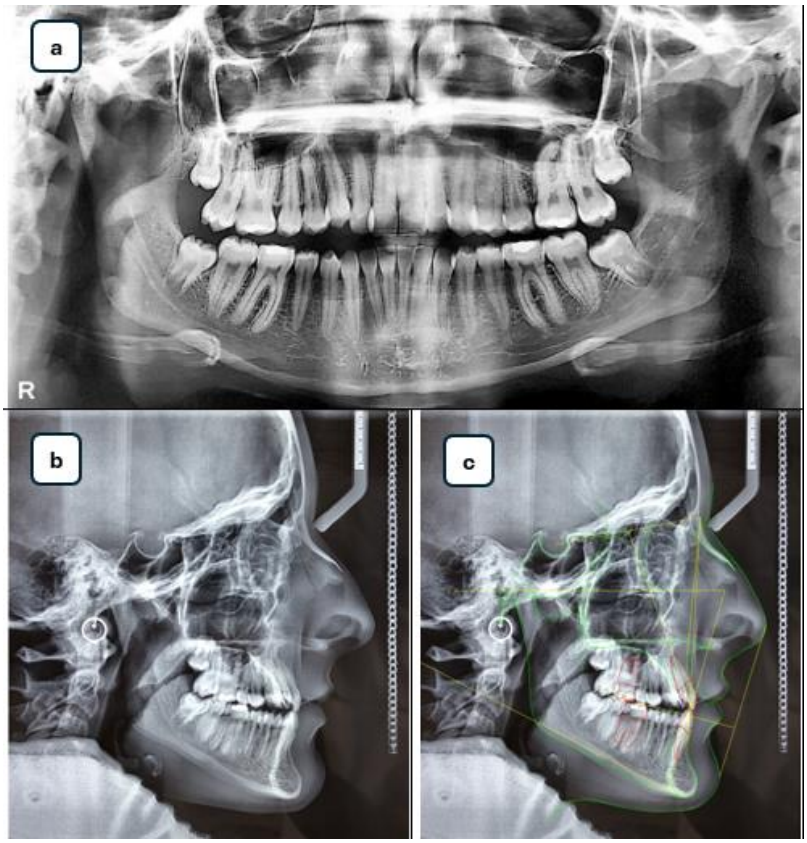

Figure 2: Pretreatment records: (a) panoramic radiograph, (b) lateral cephalometric radiograph, and (c) lateral cephalometric tracing

Alternative Treatment

Given the severity of the skeletal discrepancy and the patient's age, orthognathic surgery was initially recommended upon the completion of growth as the preferred treatment modality to achieve optimal skeletal and facial correction. However, the patient's parents were reluctant to undergo conventional orthognathic surgery. Therefore, surgically assisted BAMP was considered as an alternative approach. The patient and her parents were informed that, although this approach involved a less invasive surgical procedure and was expected to impose a lower treatment burden, its ability to achieve an ideal skeletal and facial outcome was less predictable than that of conventional orthognathic surgery. After discussing the potential benefits, limitations, and uncertainties of the proposed approach, the patient and her parents decided to proceed with BAMP.

Intervention

The treatment protocol was divided into four phases: (1) placement of maxillary and mandibular miniplates (2) bone-anchored maxillary protraction (3) maxillary expansion and (4) fixed orthodontic treatment.

Written informed consent was obtained from the patient's parents for publication of this case report and the accompanying clinical images. The nature and purpose of the report were explained to them, including the use of relevant clinical and radiographic information. They were informed that identifying details would be omitted to protect the patient's privacy, and that the report and images would be used for academic and scientific purposes.

1)Placement of Maxillary and Mandibular Miniplates

Under general anesthesia, four L-shaped miniplates (Osveh Asia, Mashhad, Iran) were surgically placed. Two miniplates were positioned in the maxillary zygomatic buttress regions, and

two were placed in the mandibular canine regions. Each miniplate was fixed using two screws (Osveh Asia, Mashhad, Iran).

Bilateral cortical Le Fort I osteotomies were subsequently performed by an oral and maxillofacial surgeon using a surgical bur. The maxilla was not down-fractured, mobilized, or repositioned, and no conventional maxillary advancement was performed during the procedure. The osteotomy cuts were performed for two purposes: to reduce resistance of the maxillary skeletal structures to subsequent orthopedic protraction forces and to induce a localized inflammatory response that could activate the regional acceleratory phenomenon (RAP), thereby enhancing local bone remodeling and facilitating subsequent maxillary protraction (Figure 3).

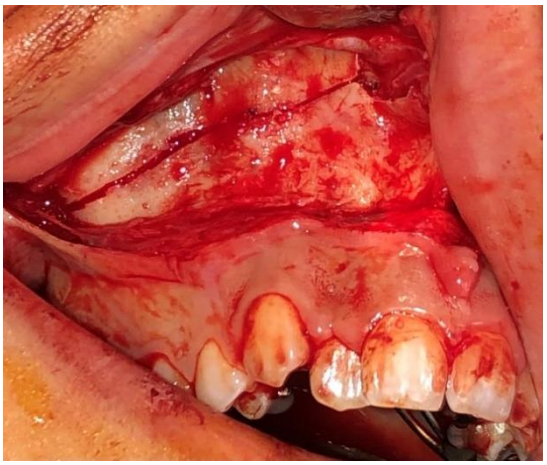

Figure 3: Cortical Le Fort I osteotomy on the right side of the patient's maxilla.

2)Bone-Anchored Maxillary Protraction

BAMP was initiated two weeks after surgery. Bilateral Class III elastics (1/4-inch, medium; American Orthodontics, Sheboygan, WI, USA), with a manufacturer-specified force of 4.5 oz (approximately 128 g), were applied between the maxillary and mandibular miniplates. The patient was instructed to replace the elastics every 24 hours and to wear them full time, except during meals, according to the prescribed schedule.

The elastic wear protocol involved wearing them constantly for the first 6 months and then at night only for the next 7 months. Total active protraction time was 13 months.

3)Maxillary Expansion

Maxillary expansion was initiated simultaneously with BAMP. The conventional tooth-borne Hyrax screw(Leon, Italy) was activated once daily by the patient, with each activation corresponding to 0.25 mm of nominal screw advancement. Active expansion continued for 45 days. At the end of this period, the screw was stabilized using flowable composite resin, and the appliance was maintained as a retainer for an additional six months. The total nominal screw activation was 11.25 mm; however, actual skeletal and dental transverse changes were not quantitatively measured (Figure 4).

4)Fixed Orthodontic Treatment

Fixed orthodontic treatment was initiated using a preadjusted edgewise appliance system (MBT prescription, 0.022-inch slot; Sino Ortho, China). The mandibular arch was bonded 2 months after BAMP was initiated, followed by bonding of the maxillary arch after completion of active expansion.



Figure 4: Before and after the expansion.

Initial alignment was performed using 0.014-inch and 0.016-inch nickel–titanium archwires (SINO ORTHODONTIC, China). Subsequently, an 0.018-inch stainless-steel archwire was used in the maxillary arch, while a 0.016×0.022-inch stainless-steel archwire was used in the mandibular arch for leveling and further occlusal correction. Vertical elastics (1/4-inch, medium; American Orthodontics, Sheboygan, WI, USA) were incorporated during this phase.

Cross-elastics were also used to improve the posterior occlusal relationship, particularly on the right side. During the finishing stage, 0.018-inch stainless-steel archwires were used in the upper and lower arches, together with dental Class III and vertical elastics(1/4-inch, medium; American Orthodontics, Sheboygan, WI, USA), to refine the inter-arch relationship and achieve final occlusal settling.

The total duration of comprehensive orthodontic treatment was 21 months.

Complications and Treatment-related Events

During treatment, the mandibular left miniplate became partially covered by overlying soft tissue. Surgical exposure of this miniplate was therefore required approximately 12 months after its placement. The miniplates remained in place after completion of orthodontic treatment.

Outcome

At the end of treatment, bilateral Class I molar and canine relationships were achieved. The anterior crossbite was corrected, and the final overjet and overbite were both approximately 1 mm. The posterior crossbite showed substantial improvement.

The maxillary and mandibular dental midlines remained deviated to the right relative to the facial skeletal midline. Extraoral evaluation revealed a slight improvement in the facial profile (Figure 5).



Figure 5: Post-treatment records: extraoral and intraoral photographs.

The post-treatment cephalometric analysis showed a modest changes in the sagittal skeletal relationship, with SNA increasing from 78.2° to 79.5° and SNB from 80.6° to 81.2°. The ANB angle improved from −2.4° to −1.7°, while the Wits appraisal improved from −7.5 mm to −1.2 mm. The FMA decreased from 25.9° to 24.2°, indicating a reduction in the mandibular plane angle. Regarding dentoalveolar changes, U1-SN decreased from 104.5° to 102.8°, indicating a slight reduction in maxillary incisor inclination, whereas IMPA increased from 80.6° to 83.3°, indicating increased mandibular incisor inclination (Figure 6).

Figure 7 presents a cephalometric superimposition of the pretreatment and post-treatment tracings, illustrating the overall skeletal and dentoalveolar changes observed during treatment.

In General, these findings suggest an improvement in the sagittal skeletal relationship accompanied by changes in both maxillary and mandibular incisor inclinations.

No post-treatment follow-up records were available; therefore, the long-term stability of the achieved occlusal and cephalometric outcomes could not be assessed.

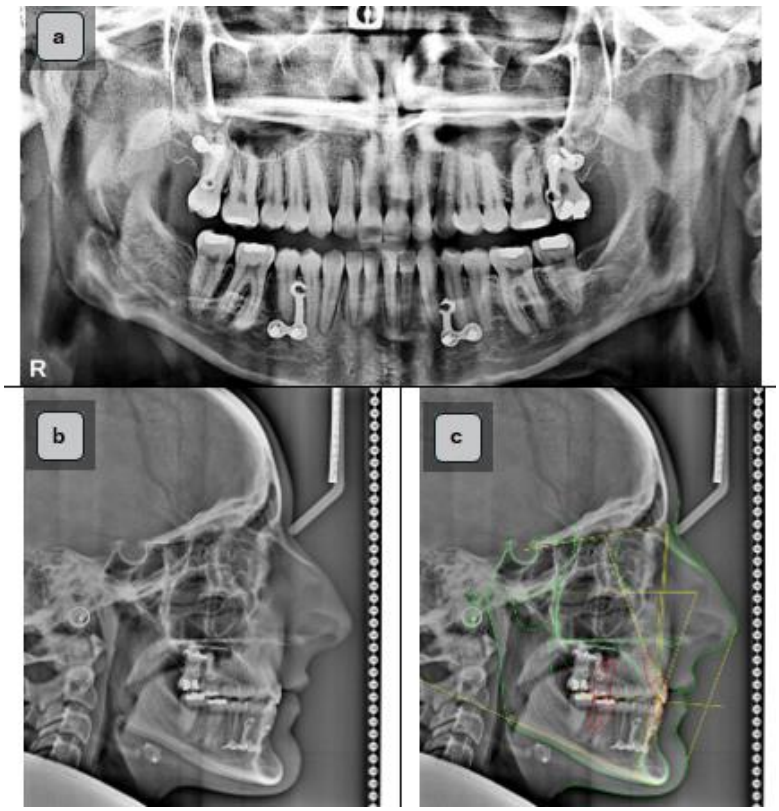

Figure 6: Post-treatment records: (a) panoramic radiograph, (b) lateral cephalometric radiograph, and (c) lateral cephalometric tracing

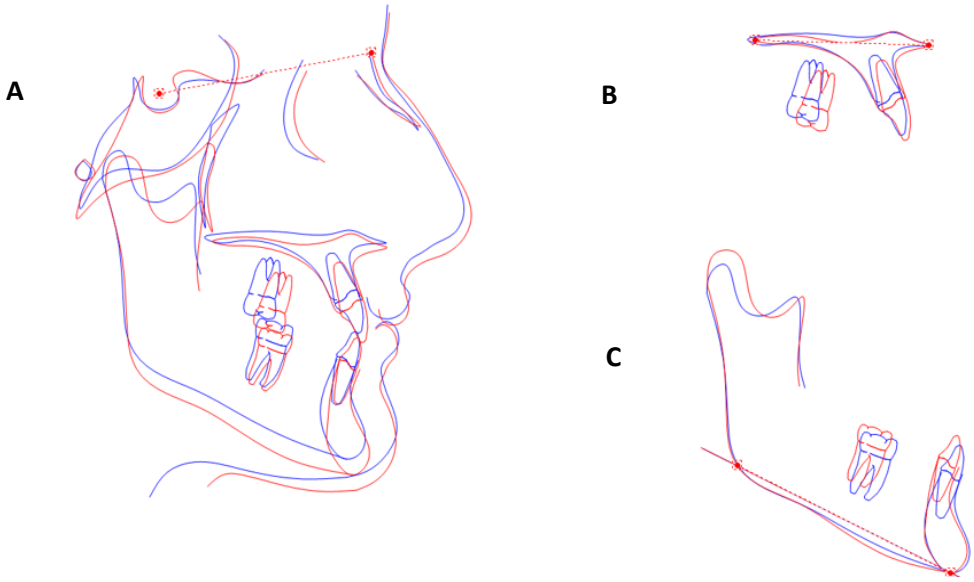

Figure 7: Cephalometric superimpositions of pretreatment and post-treatment tracings: (A) overall cranial base superimposition; (B) maxillary regional superimposition; and (C) mandibular regional superimposition. Red and blue lines represent the post-treatment and pretreatment tracings, respectively.

Discussion

This case describes treatment of skeletal Class III malocclusion with maxillary transverse deficiency using cortical bilateral Le Fort I osteotomy, four-miniplate bone-anchored maxillary protraction, concurrent tooth-borne expansion, and fixed orthodontics. This approach was selected after the patient and her parents declined conventional orthognathic surgery, initially recommended for optimal skeletal and facial correction. The aim was to improve sagittal and transverse occlusal relationships with a less invasive surgical approach, while recognizing its lower predictability for skeletal and facial correction.

Conventional facemask treatment can produce favorable skeletal changes in growing patients, but dental anchorage may cause dentoalveolar compensation, particularly maxillary incisor proclination. A systematic review and meta-analysis by Rutili et al. found significantly less maxillary incisor proclination with skeletally anchored than tooth-anchored facemask protocols; the greater SNA increase with skeletal anchorage was clinically small (3). These findings support skeletal anchorage but are not direct evidence of BAMP effectiveness. BAMP, introduced by De Clerck et al., uses maxillary and mandibular miniplates connected by Class III elastics (2). Although subsequent studies examined different anchorage designs and their dentoskeletal and soft tissue effects (8,9), systematic reviews and network meta-analyses highlight heterogeneity and limitations in the evidence (10–12). Thus, changes in this case should be interpreted descriptively, not as evidence of this protocol's independent effectiveness or superiority.

Bilateral Le Fort I osteotomies were performed before protraction. Yilmaz et al. described corticotomy-assisted maxillary protraction with skeletal anchorage and Class III elastics, using an incomplete Le Fort I osteotomy to reduce resistance to maxillary displacement (13). More recently, Bayraktar et al. evaluated corticotomy-assisted maxillary protraction using different skeletal anchorage configurations. The greatest maxillary advancement (3.2 ± 2.2 mm) was observed in the group receiving horizontally positioned miniplates below the incomplete Le Fort I osteotomy line. Unlike their protocol, which involved incomplete Le Fort I osteotomy, the present case involved complete cortical bilateral Le Fort I osteotomy cuts without maxillary down-fracture or mobilization(17).

In this case, no down-fracture, mobilization, or repositioning of the maxilla was performed. The procedure therefore differed from conventional Le Fort I advancement and complete maxillary mobilization. While the rationale behind it is similar to what has been suggested by Yilmaz et al.(13), there is no evidence available on whether the extent of osteotomy performed was similar to what has been mentioned. Furthermore, the potential contribution of RAP and the osteotomy itself to the treatment outcome cannot

be isolated from the effects of BAMP, expansion, and fixed orthodontic treatment.

Sagittal cephalometric measurements showed modest changes. SNA increased from 78.2° to 79.5°, SNB from 80.6° to 81.2°, and ANB improved from −2.4° to −1.7°. Wits appraisal improved by 6.3 mm, from −7.5 to −1.2 mm; however, Wits is influenced by the functional occlusal plane and should not be interpreted as an equivalent amount of skeletal correction(18).

Dentoalveolar measurements showed a 1.7° decrease in U1-SN (104.5° to 102.8°) and a 2.7° increase in IMPA (80.6° to 83.3°), suggesting slight reduction in maxillary incisor inclination and increased mandibular incisor inclination, respectively. These changes may reflect the effects of fixed orthodontic mechanics and the contribution of BAMP alone cannot be determined. The FMA decreased by 1.7°, from 25.9° to 24.2°, indicating a modest reduction in mandibular plane inclination. This finding may be consistent with a mild counterclockwise mandibular rotation.

Bilateral crossbite was corrected using a conventional tooth-borne Hyrax activated concurrently with BAMP. In this regard, Valls-Ontañón et al. described a combined ortho-surgical approach integrating surgically assisted miniscrew-assisted rapid palatal expansion with miniplate-anchored maxillary protraction to address transverse and sagittal maxillary deficiencies (19). Elnagar et al. reported that transverse deficiency did not spontaneously resolve after miniplate-anchored protraction (14), while it was variable evidence for additional skeletal benefits from combining expansion and protraction (15,16).

Miniplate stability is another consideration in BAMP. In a multicenter retrospective study of 218 patients, Van Hevele et al. reported high overall miniplate survival, although cephalometric changes in the subgroup with available radiographs were relatively modest (20). In this patient, the left mandibular miniplate became partially covered by soft tissue and required surgical uncovering approximately 12 months after placement. This highlights the need to monitor soft tissue coverage and device accessibility.

Limitations

Several limitations should be considered when interpreting this case. First, this is a single-patient report including surgical weakening of selected maxillary resistance structures, four-miniplate BAMP, maxillary expansion, and fixed orthodontic treatment. Second, objective skeletal maturity records were unavailable, limiting the assessment of the patient's residual growth potential at treatment initiation. Third, radiographic and clinical evaluations were not available before the initiation of fixed orthodontic treatment; therefore, it was not possible to isolate the exact therapeutic effects exclusively attributable to the expansion and BAMP protocols. Finally, no post-treatment follow-up was performed; therefore, the long-term stability and durability of the achieved occlusal and skeletal outcomes could not be assessed. Further follow-up with standardized clinical photographs, radiographs, and quantitative measurements would be necessary to evaluate the maintenance of treatment results over time.

Conclusion

In this adolescent patient with skeletal Class III malocclusion and maxillary transverse deficiency, the combination of bilateral cortical Le Fort I osteotomies, four-miniplate BAMP, concurrent tooth-borne maxillary expansion, and fixed orthodontic treatment successfully corrected the anterior and posterior crossbites and achieved an acceptable occlusal relationship. While this case illustrates a potential alternative protocol for a patient who declined conventional orthognathic surgery, the observed skeletal changes were modest. Therefore well-controlled studies with long-term follow-up are necessary to establish the efficacy, predictability, and stability of this combined approach.

Acknowledgments

None.

Conflict of Interests

No potential conflict of interest relevant to this article was reported.

Data Availability

The data supporting the findings of this study are available from the corresponding author upon reasonable request.

Funding

This research received no specific grant from funding agencies in the public, commercial, or not-for-profit sector.

Authors' Contributions

Alireza Ghasemzadeh: treatment plan, orthodontic treatment

Erfan Shadi: Data analysis, Manuscript writing

References

1. De Clerck HJ, Cornelis MA, Cevidanes LH, Heymann GC, Tulloch CJ. Orthopedic traction of the maxilla with miniplates: a new perspective for treatment of midface deficiency. J Oral Maxillofac Surg. 2009;67(10):2123-9. doi: 10.1016/j.joms.2009.03.007.
2. De Clerck H, Cevidanes L, Baccetti T. Dentofacial effects of bone-anchored maxillary protraction: a controlled study of consecutively treated Class III patients. Am J Orthod Dentofacial Orthop. 2010;138(5):577-81. doi: 10.1016/j.ajodo.2009.10.037.
3. Rutili V, Nieri M, Franceschi D, Pierleoni F, Giuntini V, Franchi L. Effects produced by the facemask with and without skeletal anchorage for the orthopaedic treatment of Class III malocclusion in growing patients: a systematic review and meta-analysis of RCTs. Eur J Orthod. 2023;45(2):157-168. doi: 10.1093/ejo/cjac048.
4. De Clerck H, Nguyen T, de Paula LK, Cevidanes L. Three-dimensional assessment of mandibular and glenoid fossa changes after bone-anchored Class III intermaxillary traction. Am J Orthod Dentofacial Orthop. 2012;142(1):25-31. doi: 10.1016/j.ajodo.2012.01.017.
5. Mandall N, Aleid W, Cousley R, Curran E, Caldwell S, DiBiase A, etal. The effectiveness of bone anchored maxillary protraction (BAMP) in the management of class III skeletal malocclusion in children aged 11-14 years compared with an untreated control group: A multicentre two-arm parallel randomised controlled trial. J Orthod. 2024;51(3):228-239. doi: 10.1177/14653125241255139.
6. Kathem SJ, Pedersen TK. Treatment modalities in bone-borne maxillary protraction in children with maxillary retrognathism: a systematic review and meta-analysis. Eur J Orthod. 2025 ;47(4):cjaf023. doi: 10.1093/ejo/cjaf023.
7. Esposito C, Judd J, Rezende Silva E, Xie J, Blakey G, Jacox LA. Longitudinal outcomes of bone-anchored maxillary protraction treatment. Am J Orthod Dentofacial Orthop. 2026;170(4):541-553.e9. doi: 10.1016/j.ajodo.2026.04.018.
8. Elnagar MH, Elshourbagy E, Ghobashy S, Khedr M, Evans CA. Comparative evaluation of 2 skeletally anchored maxillary protraction protocols. Am J Orthod Dentofacial Orthop. 2016;150(5):751-762. doi: 10.1016/j.ajodo.2016.04.025.
9. Elnagar MH, Elshourbagy E, Ghobashy S, Khedr M, Kusnoto B, Evans CA. Three-dimensional assessment of soft tissue changes associated with bone-anchored maxillary protraction protocols. Am J Orthod Dentofacial Orthop. 2017;152(3):336-347. doi: 10.1016/j.ajodo.2017.01.022.
10. Cornelis MA, Tepedino M, Riis NV, Niu X, Cattaneo PM. Treatment effect of bone-anchored maxillary protraction in growing patients compared to controls: a systematic review with meta-analysis. Eur J Orthod. 2021;43(1):51-68. doi: 10.1093/ejo/cjaa016.
11. Hu S, An K, Peng Y. Comparative efficacy of the bone-anchored maxillary protraction protocols for orthopaedic treatment in skeletal Class III malocclusion: A Bayesian network meta-analysis. Orthod Craniofac Res. 2022;25(2):243-250. doi: 10.1111/ocr.12532.
12. Wang J, Yang Y, Wang Y, Zhang L, Ji W, Hong Z, etal. Clinical effectiveness of different types of bone-anchored maxillary protraction devices for skeletal Class III malocclusion: Systematic review and network meta-analysis. Korean J Orthod. 2022;52(5):313-323. doi: 10.4041/kjod21.264.
13. Yilmaz HN, Garip H, Satilmis T, Kucukkeles N. Corticotomy-assisted maxillary protraction with skeletal anchorage and Class III elastics. Angle Orthod. 2015;85(1):48-57. doi: 10.2319/121513-921.1.
14. Elnagar MH, Elshourbagy E, Ghobashy S, Khedr M, Evans CA. Dentoalveolar and arch dimension changes in patients treated with miniplate-anchored maxillary protraction. Am J Orthod Dentofacial Orthop. 2017;151(6):1092-1106. doi: 10.1016/j.ajodo.2016.10.038.
15. Foersch M, Jacobs C, Wriedt S, Hechtner M, Wehrbein H. Effectiveness of maxillary protraction using facemask with or without maxillary expansion: a systematic review and meta-analysis. Clin Oral Investig. 2015;19(6):1181-92. doi: 10.1007/s00784-015-1478-4.
16. Almuzian M, McConnell E, Darendeliler MA, Alharbi F, Mohammed H. The effectiveness of alternating rapid maxillary expansion and constriction combined with maxillary protraction in the treatment of patients with a class III malocclusion: a systematic review and meta-analysis. J Orthod. 2018;45(4):250-259. doi: 10.1080/14653125.2018.1518187.
17. Bayraktar AU, Yağci A, Ocal O, Demirbas AE. Corticotomy-assisted application of different miniplates and intermaxillary elastics: Comparison of the effectiveness after growth spurt in individuals with skeletal Class III malocclusion. J Orofac Orthop. 2026 Jun 15. doi:10.1007/s00056-026-00675-5.
18. Serafin M, Baldini B, Rossi O, Perrotti G, Caprioglio A. Novel approach to three-dimensional intermaxillary skeletal assessment: correlation between the ANB angle and the bisector Wits appraisal. J Orofac Orthop. 2026;87(3):280-7. doi:10.1007/s00056-025-00583-0.
19. Valls-Ontañón A, Lázaro-Abdulkarim A, Lorente-Martín C, Vicente-Martí C, Starch-Jensen T, Hernández-Alfaro F. Simultaneous ortho-surgical expansion and protraction of the maxilla in patients with mature midpalatal suture: A technical note. J Craniomaxillofac Surg. 2025;53(3):193-5. doi:10.1016/j.jcms.2024.11.007.
20. Van Hevele J, Nout E, Claeys T, Meyns J, Scheerlinck J, Politis C. Bone-anchored maxillary protraction to correct a class III skeletal relationship: A multicenter retrospective analysis of 218 patients. J Craniomaxillofac Surg. 2018;46(10):1800-1806. doi: 10.1016/j.jcms.2018.07.007.