Iran J Orthod. 2026 June; 21(1):e1419. doi:10.22034/ijo.2026.2087651.1419.
Published online 2026 June 1 Research Article
Original Article **Open Access**

Unilateral Uprighting and Distalization of the Severely Crowded Posterior Mandibular Segment Using a Buccal Shelf Mini Implant: A Case Report

Mostafa Abtahi [1], Alireza Ghasemzadeh [2*], Ali Foroughi [3]

[1] Associate Professor of Orthodontics, Department of Orthodontics, School of Dentistry, Mashhad University of Medical Sciences, Mashhad, Iran.
[2] Assistant Professor, Department of Orthodontics, School of Dentistry, Mashhad University of Medical Sciences, Mashhad, Iran
[3] Resident, Department of Orthodontics, School of Dentistry, Mashhad University of Medical Sciences, Mashhad, Iran.

***Corresponding author:** Alireza Ghasemzadeh

Address: Department of Orthodontics, School of Dentistry, Park Square, Mashhad, Iran

E-mail: alirezaghasemzadehd75@gmail.com

Received: 2026 January 09; **Revised:** 2026 May 13; **Accepted:** 2026 May 14

Abstract

Aim

Severe lingual tipping of mandibular posterior teeth may result in traumatic occlusal contacts, periodontal complications, impaired mastication, and compromised oral hygiene. Conventional orthodontic mechanics can correct these discrepancies; however, they are often associated with undesirable side effects.This case report describes the management of severe unilateral lingual tipping and crowding of the mandibular posterior segment using a buccal shelf miniscrew-supported segmental uprighting approach.

Case Presentation

A 17-year-old male patient presented with severe lingual tipping of the mandibular left posterior segment associated with localized crowding, traumatic occlusal contacts, masticatory discomfort, and transverse discrepancy. Clinical and radiographic examination revealed lingual inclination of the mandibular left second premolar and first molar, severe mesial root angulation of the mandibular left canine, overeruption of the maxillary left second premolar, and asymmetry of both midlines. The patient exhibited a skeletal Class I relationship with acceptable facial balance.

Interventions

Treatment was completed over 18 months in three phases. In phase I, retained roots of the maxillary left first molar were extracted, and intrusion of the overerupted maxillary left second premolar was achieved using two miniscrews (1.6×8 mm) and elastic power chains. In phase II, the mandibular left second molar was extracted to facilitate distalization and uprighting because of the favorable position of the developing third molar. A buccal shelf miniscrew (2×10 mm) was inserted to provide skeletal anchorage, and elastic chains were applied to bonded buttons for simultaneous uprighting and distalization of the mandibular posterior segment. In phase III, comprehensive fixed orthodontic treatment was performed for alignment, leveling, crossbite correction, and final occlusal detailing using cross-elastics and auxiliary mechanics.

Conclusion

Favorable uprighting and distalization of the mandibular left posterior segment were achieved. Improvement of the posterior crossbite, dental asymmetry, and localized crowding was observed, and functional occlusal relationships were established. Traumatic occlusal contacts and masticatory discomfort were reduced following treatment. In addition, the mandibular left third molar erupted in an acceptable position**.**

Keywords: Buccal shelf miniscrew, Molar distalization, Temporary anchorage device.

Copyright © 2026, Author(s). This is an open-access article distributed under the terms of the Creative Commons Attribution-NonCommercial 4.0 International License (http://creativecommons.org/licenses/by-nc/4.0/) which permits copy and redistribute the material just in noncommercial usages, provided the original work is properly cited.

Background

Lingual inclination of mandibular posterior teeth is usually observed as a physiological feature, particularly in second molars, which are characteristically tilted lingually relative to the alveolar ridge. This inclination may be further influenced by skeletal pattern and alveolar bone limitations, rather than being reported as a discrete epidemiological prevalence (1,2).

Tipping in mandibular posterior teeth occurs in 0.03–0.3% of the general population and 2–3% of orthodontic patients (3).

Many causative factors contribute to the abnormal eruption of the mandibular molars and premolars: lack of arch length, abnormal erupting angulation, premature eruption of the mandibular third molar, alteration of the dental follicle, and other iatrogenic factors (4-6).

It has also been reported that individuals with a high-angle facial pattern tend to exhibit narrower dental arch and basal bone widths compared with other facial types, which may contribute to altered inclination of the posterior teeth (7).

To achieve proper occlusal contacts and prevent further periodontal problems, uprighting of lingually tipped posterior teeth is recommended. If not properly corrected, lingually tilted posterior teeth may lead to adverse outcomes, including periodontal disease, occlusal disharmony, and mechanical limitations (3,8,9).

In recent years, mini-implants have been widely adopted as an effective source of skeletal anchorage in orthodontic treatment.

The use of temporary anchorage devices (TADs) has significantly enhanced the biomechanics of unilateral distalization. TADs, especially those inserted in the buccal shelf or palatal areas, offer stable skeletal support for en-masse distalization and segmental tooth movement without negatively affecting anterior esthetics or occlusal function (10). Such an approach is particularly beneficial in adult patients with mild skeletal discrepancies, where treatment goals primarily focus on alleviating crowding, correcting asymmetry, and enhancing soft-tissue harmony.

In adult patients presenting with unilateral malocclusions, extraction of a single posterior tooth may serve as a conservative alternative to full-arch extractions or orthognathic surgery (11).

This report highlights the use of a TAD system in the mandible to manage a lingually tipped mandibular multi-tooth segment.

Case Presentation

A 17-year-old male patient was referred with the chief complaint of difficulty in chewing and dental irregularity. The patient reported no significant medical or previous dental history.

Clinical examination revealed a complete permanent dentition, except for the third molars, which had not yet erupted. The patient's lateral cephalogram demonstrated a skeletal Class I relationship with acceptable soft tissue balance in both frontal and profile views. On the right side, both molar and canine relationships were Class I. On the left side, however, the canine relationship was slightly Class II, while the molar relationship was super Class I. Intraoral examination also revealed severe mandibular crowding and noticeable dental asymmetry on the left side. In addition, a deviation of the dental midline toward the right side was observed in both the maxillary and mandibular arches.

Further evaluation of the maxillary arch showed that the left first molar exhibited widening of the periodontal ligament space and evidence of incomplete root canal treatment. Clinically, no portion of the tooth crown was visible in the oral cavity, and only the roots remained submerged beneath the gingival tissue. In the mandibular arch, the left canine displayed severe mesial root angulation. Moreover, the maxillary left second premolar demonstrated significant overeruption as a result of the absence of occlusal contact with its antagonist and presented with a buccal crossbite. This transverse discrepancy contributed to traumatic occlusal interferences and was associated with a constricted mandibular arch (Figures 1–3).

Despite these findings, the patient maintained good oral hygiene and showed no signs of active periodontal disease.

Based on the clinical and radiographic findings, a comprehensive orthodontic treatment plan was proposed. The primary objective of treatment was the correction of mandibular crowding and dental asymmetry through uprighting of the lingually tipped mandibular teeth using temporary anchorage devices (TADs). This would be followed by comprehensive orthodontic alignment and final occlusal detailing to achieve optimal intercuspation and a functional occlusal relationship. One of the main advantages of this approach is the preservation of the patient's natural dentition while re-establishing a proper axial inclination and functional stability of the posterior teeth.

The proposed treatment plan, including its objectives, procedures, and expected outcomes,

was thoroughly explained to the patient and his parents. After explaining the benefits and potential alternatives, they agreed to proceed with the recommended orthodontic treatment. Written informed consent for treatment plan; also, publication of the patient's clinical data and records was obtained from the patient's parents.



Figure 1. pre-treatment intraoral and extraoral photographs.



Figure 2. Pre-treatment panoramic radiograph



Figure 3. Pre-treatment lateral cephalogram

Intervention

Phase I

The treatment commenced with the surgical extraction of the retained roots of the maxillary left first molar. Then, the focus shifted to managing the overerupted maxillary left second premolar, which required significant intrusion to re-establish a proper occlusal plane.

To achieve this, a skeletal anchorage system was used. Two miniscrews (G2 1.6×8 mm, Jeil Medical Corporation , South Korea) were placed at the mesiobuccal and distopalatal area of the

second premolar. To facilitate the application of intrusive forces, an orthodontic bracket was bonded to the buccal surface, and a lingual button was attached to the palatal surface of the tooth (Figure 4a).

Subsequently, elastic chains (Yahong, China) with 20 Newtons of force were inserted between the miniscrews and the attachments. This configuration enabled the delivery of a controlled, balanced intrusive force, minimizing undesirable tipping or rotation while effectively correcting the vertical position of the premolar. Maxillary TADs were subsequently relocated more gingivally to renew the palatal force vectors and suitable intrusion. After successful intrusion of the tooth, the miniscrews were removed. This phase lasted 5 months.

Phase II

At the same time, while intrusion of the maxillary left second premolar was being performed, distal drive of the mandibular left first molar was initiated. Due to the favorable angulation of the mandibular left third molar and its incomplete root formation, the mandibular left second molar was extracted. This approach was selected to facilitate correction of the molar inclination and provide adequate space for proper alignment and potential eruption of the third molar. Following extraction, two orthodontic buttons were bonded to the mandibular left first molar: one on the mesiobuccal surface and the other on the mesiolingual surface. This configuration allowed force to be applied from multiple directions and provided better control of the tooth during this movement.

Subsequently, a (G2 2×10 mm, Jeil Medical Corporation , South Korea) was inserted in the buccal shelf area to serve as a source of skeletal anchorage. The buccal shelf region was selected due to its relatively thick cortical bone and its suitability for delivering distalizing and uprighting forces to mandibular molars. Traction forces were then applied from the buccal shelf TAD to the bonded buttons on the first molar using an elastic chain (Yahong, China). A flowable composite resin was applied to the buccal shelf miniscrew to reduce mucosal irritation. (Figure 4b,4c)

To eliminate occlusal interferences during the uprighting phase and facilitate the desired tooth movement, a removable appliance was fabricated for the maxillary arch. The appliance incorporated Adams clasps on the molars and premolars to ensure adequate retention, along with a posterior bite plane to disclude the posterior teeth. The bite plane was selectively trimmed in the molar region during treatment to allow controlled vertical and transverse movements while preventing unwanted occlusal contacts that could interfere with the uprighting mechanics. This phase, from the initiation to the completion of distal drive, lasted 8 months.

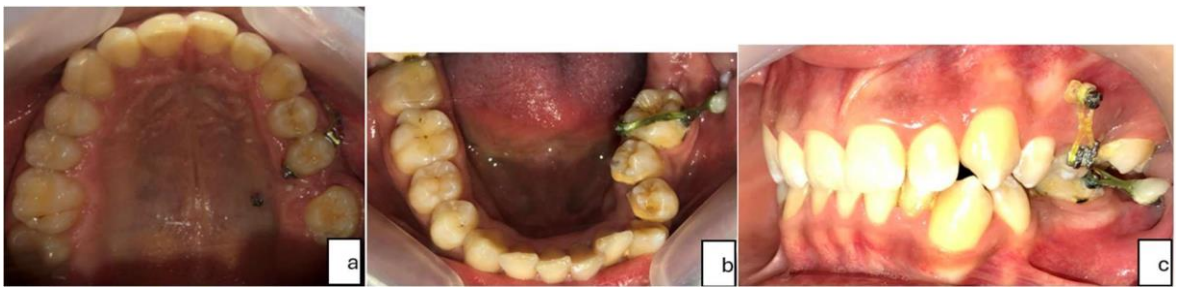

Figure 4. Treatment progress
a) upper left second premolar intrusion by buccal and lingual TADs
b) lower left first molar uprighting and distalization with buccal shelf TAD
c) premolar intrusion and molar uprighting.

Phase III

Gradually, the mandibular left first molar was uprighted and distalized. Following this phase, comprehensive fixed orthodontic treatment (MBT, 0.22 inch, Sino Ortho, China) was initiated in both arches, while the left first molar tube was attached

to the buccal shelf miniscrew using ligature wire to prevent relapse.

Orthodontic buttons were bonded on the palatal surfaces of the maxillary canine and premolars, as well as on the lingual surface of the mandibular left first molar and the mandibular premolars, to facilitate the application of cross-elastics.(Figure 5, upper)

Alignment and leveling began with 0.014- and 0.016-inch NiTi archwires. Concurrently, 1/4-inch light cross elastics were applied to correct the posterior crossbite. Subsequently, to correct the axial inclination of the canine, a box loop was incorporated into an 0.014-inch stainless steel archwire. Finishing and detailing of the occlusion were completed using 0.016×0.022 NiTi and stainless steel archwires, followed by an 0.018-inch stainless steel archwire to finalize the treatment (Figure 5, lower). This phase lasted 12 months.

Outcome

The active treatment phase was completed in 18 months. For retention, vacuum-formed clear retainers were prescribed for both arches. The patient demonstrated excellent compliance throughout the treatment period. All treatment objectives were successfully achieved by the end of therapy, including correction of midline deviation, resolution of localized crowding and dental crossbite, uprighting and distalization of the mandibular left segment, upper left first molar space closure, and alignment of both dental arches, and the left third molar was erupted in a good position (Figures 6,7s). The patient reported improved chewing ability, elimination of traumatic contacts, and satisfaction with dental alignment and facial appearance after treatment.



Figure 5. Treatment progress (Phase III).
Upper images: Fixed orthodontic treatment using cross elastics attached to the buttons.
Lower images: Box loop for distal root tipping of the canine.



Figure 6. Post-treatment extraoral views demonstrating a balanced profile and stable occlusion



Figure 7 . Post-treatment panoramic radiograph

Discussion

Management of a lingually tipped mandibular posterior segment with localized severe crowding remains a biomechanical challenge because correction requires controlled transverse uprighting while minimizing undesirable extrusion, rotational side effects, and anchorage loss. In the present case, a miniscrew-supported system provided effective three-dimensional control of a lingually tipped mandibular posterior segment with minimal dependence on patient compliance. The achieved correction improved the transverse relationship, eliminated occlusal interferences, and

facilitated the establishment of a more functional and stable occlusion.

Lingual inclination of mandibular posterior teeth is a normal feature of occlusion and contributes to the curve of Wilson and efficient mastication. Li et al. reported on CBCT that mandibular second molars usually show about 15–17° of lingual inclination (1). Therefore, when this inclination is excessive, occlusal harmony and periodontal stability may be affected. In the present case, the lingual tipping was more severe than normal and led to transverse collapse, traumatic occlusal contacts, and poor arch coordination. Therefore, orthodontic uprighting was indicated not only for alignment purposes, but also to bring the teeth into a more favorable functional position.

Several etiologic factors have been associated with posterior segment tipping, including premature tooth loss, arch length deficiency, altered eruption patterns, and muscular imbalance (4,5).

It has been emphasized that mandibular molars are particularly susceptible to abnormal inclination due to their eruption path and the morphology of the surrounding alveolar bone (6). In the present case, mandibular crowding and posterior arch collapse likely contributed to the abnormal eruption trajectory and progressive lingual displacement of the involved segment.

Conventional mechanics for molar uprighting often rely on dental anchorage and may produce reciprocal effects, such as extrusion of adjacent teeth, incisor flaring, or unwanted changes in the occlusal plane. The introduction of TADs has substantially expanded the biomechanical possibilities for managing complex tooth movements. Cope described TADs as a paradigm shift in orthodontic anchorage because they allow clinicians to obtain stationary anchorage independent of patient cooperation (12). Similarly, Umalkar et al. emphasized that skeletal anchorage systems provide more predictable force application and reduce undesirable reactive movements compared with conventional approaches (13).

In the current report, a single buccal shelf miniscrew was selected as the primary anchorage unit for transverse uprighting of the mandibular posterior segment and space regaining by lower arch distalization. The mandibular buccal shelf offers several biomechanical advantages, including relatively thick cortical bone and increased interradicular safety. CBCT-based investigations have shown that the mandibular second molar region frequently presents thicker buccal cortical support compared with the lingual aspect, making this area favorable for extra-alveolar TAD placement (13). The use of a buccal shelf TAD in this case enabled direct force delivery to the lingually tipped teeth while minimizing the need for anchorage from adjacent dentition.

Mah et al. reported successful uprighting of impacted mandibular molars using dual miniscrew mechanics that allowed controlled root movement and minimized undesirable extrusion (6).

Lee etal showed that buccal shelf bone screws provide effective, minimally invasive anchorage for mandibular whole-arch retraction in Class III patients (14).

Consistent with these findings, the present case showed that skeletal anchorage can effectively manage complex posterior segment discrepancies while preserving surrounding dentition and periodontal support.

The chain used between TAD and lingual/buccal button attachments produced a buccally directed uprighting force, and the short moment arm allowed efficient transverse correction. The removable bite plane helped eliminate occlusal interferences that could limit tooth movement. This approach allowed gradual buccal uprighting while avoiding excessive occlusal load on the teeth. Gradual trimming of the bite plane also helped control vertical setting during treatment.

One important consideration during transverse uprighting of mandibular posterior teeth is the biologic limitation imposed by alveolar bone anatomy. Li et al. highlighted that mandibular second molars possess thinner lingual alveolar bone and are positioned closer to the lingual cortical plate than first molars (1). Excessive or uncontrolled buccolingual movement beyond the alveolar bone may increase the risk of dehiscence, fenestration, and root resorption. Consequently, careful force control and periodic monitoring are essential during uprighting procedures. In the present case, gradual activation and skeletal anchorage allowed controlled tooth movement while maintaining periodontal integrity throughout treatment.

In this regard, Tulloch emphasized that orthodontic uprighting can significantly improve periodontal prognosis and facilitate restorative stability by re-establishing proper tooth angulation and occlusal loading (9). Given the patient's young age, conservative orthodontic correction was the most biologically favorable option. The present report also highlights the versatility of combining skeletal anchorage with auxiliary mechanics during finishing stages. Following transverse correction, conventional fixed appliance therapy and interarch elastics were used to refine intercuspation and root

positioning. This sequential approach allowed efficient correction of the primary transverse problem before comprehensive detailing, thereby simplifying overall biomechanics.

The miniscrew-supported system used in the present case provided several biomechanical advantages for the management of this uncommon presentation. First, skeletal anchorage minimized reciprocal effects on adjacent teeth and allowed direct application of buccally directed uprighting forces to the involved segment. Second, the use of a removable bite plane eliminated occlusal locking and facilitated transverse correction by discluding the posterior teeth during active movement. Third, gradual activation permitted controlled dentoalveolar adaptation and improved periodontal safety during correction of the severely displaced segment. In general, these factors contributed to successful correction without the need for more invasive restorative or surgical interventions.

From a clinical perspective, this case emphasizes that severe lingual tipping of a mandibular posterior segment should not be regarded merely as a localized alignment problem, but rather as a complex dentoalveolar discrepancy with functional, occlusal, and periodontal implications. Early diagnosis and biomechanically controlled intervention are essential to prevent progression of arch collapse, traumatic occlusion, and periodontal compromise. The favorable outcome observed in this case suggests that TAD-supported segmental uprighting may represent an effective conservative alternative for managing similar complex transverse discrepancies in adolescent patients.

Limitations

Despite the successful outcome, long-term post-treatment follow-up is necessary to evaluate the stability of transverse uprighting achieved with TAD-supported mechanics. Moreover, Future studies with larger sample sizes and CBCT-based assessments would be valuable for evaluating periodontal response, root position changes, and long-term stability after correction of severe lingual tipping.

Conclusion

This case suggests that a miniscrew-supported system may be a useful and relatively conservative option for uprighting a lingually tipped mandibular tooth segment. The use of skeletal anchorage in the buccal shelf helped limit unwanted movement of adjacent teeth and allowed for more controlled force application. Attention to biomechanics and force magnitude is particularly important in the mandibular molar region, where cortical bone thickness and root position may restrict movement. In appropriately selected cases, this approach may improve functional outcomes.

Acknowledgments

None.

Conflicts of Interest

The authors declare no conflicts of interest.

Data Availability Statement

The data that support the findings of this study are available upon request.

Funding

None.

References

1. Li C, Dimitrova B, Boucher NS, Chung CH. Buccolingual inclination of second molars in untreated adolescents and adults with near normal occlusion: A CBCT study. J Clin Med. 2022;11(22):6629. doi: 10.3390/jcm11226629.
2. Tseng YC, Chang HP, Chou TM. Tooth morphometry in lingual orthodontics. Kaohsiung J Med Sci. 2004;20(12):586-90. doi: 10.1016/S1607-551X(09)70263-3.
3. Magkavali-Trikka P, Emmanouilidis G, Papadopoulos MA. Mandibular molar uprighting using orthodontic miniscrew implants: a systematic review. Prog Orthod. 2018;19(1):1. doi: 10.1186/s40510-017-0200-2.
4. Lin YT, Lin WH, Lin YT. Immediate and six-month space changes after premature loss of a primary maxillary first molar. J Am Dent Assoc. 2007;138(3):362-8. doi: 10.14219/jada.archive.2007.0169.
5. Zhao J, Jin H, Li X, Qin X. Dental arch spatial changes after premature loss of first primary molars: a systematic review and meta-analysis of split-mouth studies. BMC Oral Health. 2023;23(1):430. doi: 10.1186/s12903-023-03111-x.
6. Mah SJ, Won PJ, Nam JH, Kim EC, Kang YG. Uprighting mesially impacted mandibular molars with 2 miniscrews. Am J Orthod Dentofacial Orthop. 2015;148(5):849-61. doi: 10.1016/j.ajodo.2015.07.027.
7. Cui X, Tang H, Zhang Y, Zheng Y, Lin X. Relationship of buccolingual inclination between the alveolar

bone and first molar in different vertical facial types: A CBCT study. J Stomatol Oral Maxillofac Surg. 2024;125(12 Suppl 2):101974. doi: 10.1016/j.jormas.2024.101974.
8. Barros SE, Faria J, Jaramillo Cevallos K, Chiqueto K, Machado L, Noritomi P. Torqued and conventional cantilever for uprighting mesially impacted molars: A 3-dimensional finite element analysis. Am J Orthod Dentofacial Orthop. 2022;162(4):e203-e215. doi: 10.1016/j.ajodo.2022.07.014.
9. Tulloch JF. Uprighting molars as an adjunct to restorative and periodontal treatment of adults. Br J Orthod. 1982;9(3):122-8. doi: 10.1179/bjo.9.3.122.
10. Nguyen VA, Ha TMA. Treatment of a severe class II subdivision malocclusion following failed bimaxillary anterior segment osteotomy: a case report. BMC Oral Health. 2025;25(1):612. doi: 10.1186/s12903-025-06000-7.
11. Nguyen VA, Vo TQP. Management of severe bimaxillary crowding using unilateral molar extraction and miniscrew-assisted posterior distalization: A case report. Medicine (Baltimore). 2025;104(50):e46683. doi: 10.1097/MD.0000000000046683.
12. Cope JB. Temporary anchorage devices in orthodontics: A paradigm shift. Semin Orthod. 2005;11(1):3–9.doi:10.1053/j.sodo.2004.11.002.
13. Umalkar SS, Jadhav VV, Paul P, Reche A. Modern anchorage systems in orthodontics. Cureus. 2022;14(11):e31476. doi: 10.7759/cureus.31476.
14. Lee HT, Lin JH, Chang CH, Roberts WE. Retraction and rotation of the mandibular arch with buccal shelf bone screws to resolve Class III skeletal malocclusion. Angle Orthod. 2026 :e051825-395.1. doi: 10.2319/051825-395.1.