Iran J Orthod. 2026 June; 21(1):e1303. doi:10.22034/ijo.2026.2068535.1303.
Published online 2026 June 1 Research Article
Original Article **Open Access**

Gingival Crevicular Fluid MMP-9 Levels and Orthodontically Induced Root Resorption During Anterior Retraction With or Without Mini-Implant-Assisted Intrusion: A Non-Randomized Controlled Clinical Trial

EK Rishika [1], Vincy Antony [2], Anthony George [3], Prathapan Parayaruthottam [4], Syed Mustaq Ahmed [5], Muhamed Shaloob [2], Gazanafer Roshan [2]

[1] Resident, Department of Orthodontics, MES Dental College, Perinthalmanna, Kerala, India.
[2] Professor, Department of Orthodontics, MES Dental College, Perinthalmanna, Kerala, India.
[3]Professor, Department of Oral Pathology, MES Dental College, Perinthalmanna, Kerala, India.
[4] Professor, Department of Orthodontics, Government Dental College, Alappuzha, Kerala India.
[5] Professor, Department of Microbiology, MES Medical College, Perinthalmanna, Kerala, India

***Corresponding author:** Vincy Antony

Address: Department of Orthodontics, MES Dental College, Perinthalmanna, Malappuram, Kerala 679338, India

E-mail: vincyantony2008@yahoo.com

Received: 2025 August 17; **Revised:** 2026 January 01; **Accepted:** 2026 April 17

Abstract

Aim

This study aimed to compare changes in gingival crevicular fluid (GCF) matrix metalloproteinase-9 (MMP-9) levels and radiographically assessed orthodontically induced root resorption (OIRR) in patients undergoing maxillary anterior retraction with or without mini-implant–assisted intrusion.

Methods

In this clinical trial, 14 participants were allocated into two groups (n = 7 each). Group 1 underwent anterior retraction following first premolar extraction, whereas Group 2 received simultaneous intrusion and retraction using a midline mini-implant. GCF samples were collected at three time points: T0 (baseline), T1 (initiation of retraction), and T2 (three months after retraction). MMP-9 concentrations were quantified using an ELISA assay. Radiographic evaluation of OIRR via standardized RadioVisioGraphy (RVG) was performed at T0 and T2 using the Modified Malmgren Criteria. Statistical analyses using Fisher Exact, independent and paired t-tests. P-value<0.05 was considered as significant.

Results

Baseline MMP-9 concentrations were comparable between the two groups (Group 1: 0.99 ± 0.37 ng/mL; Group 2: 0.96 ± 0.10 ng/mL; $P > 0.05$). Both groups showed a significant increase in GCF MMP-9 levels from T0 to T1 and from T1 to T2. At T2, mean MMP-9 levels were significantly higher in Group 2 (2.82 ± 0.62 ng/mL) compared with Group 1 (2.12 ± 0.49 ng/mL) ($P = 0.03$), corresponding to percentage increases of 193.7% and 114.1%, respectively.

Radiographic assessment revealed no evidence of root resorption at baseline in either group. At T2, both groups demonstrated a statistically significant increase in root resorption scores compared with baseline ($P = 0.0001$). The Pearson correlation test for Group 1 showed a moderate negative correlation between T2 MMP-9 values and T2 root resorption grade ($r = -0.46$, $p = 0.299$). In Group 2 , the Pearson correlation test showed a strong negative correlation between T2 MMP-9 values and T2 root resorption grade ($r = -0.89$, $p = 0.007$).

Conclusion

Both orthodontic retraction alone and retraction combined with mini-implant–assisted intrusion were associated with increases in GCF MMP-9 levels and mild radiographic root resorption over the three-month period. Although the intrusion group showed higher MMP-9 levels, this did not lead to clear radiographic differences between the groups. This study showed a strong and statistically significant negative correlation between T2 MMP-9 levels and root resorption grade , but the overall clinical relevance of this pattern remains uncertain.

Keywords: Fixed orthodontic treatment, Gingival crevicular fluid, Matrix metalloproteinase-9, Root resorption.

Copyright © 2026, Author(s). This is an open-access article distributed under the terms of the Creative Commons Attribution-NonCommercial 4.0 International License (http://creativecommons.org/licenses/by-nc/4.0/) which permits copy and redistribute the material just in noncommercial usages, provided the original work is properly cited.

Background

Orthodontically induced root resorption (OIRR) is one of the most significant iatrogenic complications associated with orthodontic treatment. It occurs as a consequence of complex biological responses within the periodontal ligament and surrounding alveolar bone during orthodontic tooth movement. Procedures involving retraction and intrusion of maxillary anterior teeth, commonly performed in the management of deep bite and excessive gingival display, are particularly associated with an increased risk of OIRR due to the magnitude and direction of the applied orthodontic forces (1). Recent investigations have highlighted that the duration, magnitude, and distribution of orthodontic forces significantly influence periodontal tissue remodeling and may contribute to the development and severity of root resorption (2,3).

Vertical maxillary excess (VME), often manifested clinically as a "gummy smile," is characterized by excessive gingival display during smiling in patients with normal lip length. Epidemiological studies have reported a prevalence of approximately 7% in young adult males and 14% in young adult females (4,5). Management of this condition frequently involves orthodontic intrusion of the maxillary anterior teeth to reduce gingival display and improve smile aesthetics. Conventional orthodontic techniques used for this purpose include utility arches, intrusion arches, K-Sir arches, and vertical pull headgear. However, these approaches often result in undesirable side effects such as labial tipping of anterior teeth and extrusion of posterior teeth, thereby compromising treatment efficiency and anchorage control (6).

The introduction of temporary anchorage devices (TADs), particularly orthodontic mini-implants, has significantly expanded the biomechanical possibilities in modern orthodontics. Mini-implants provide reliable skeletal anchorage, allowing controlled intrusion and retraction of anterior teeth with minimal reliance on patient compliance and reduced unwanted tooth movement (7). Despite these advantages, the application of concentrated forces during mini-implant-assisted mechanics may alter stress distribution around tooth roots and potentially increase the risk of root resorption, necessitating careful biological monitoring during treatment (8).

In recent years, there has been growing interest in identifying biochemical markers that can provide early and non-invasive indications of tissue remodeling and potential root resorption during orthodontic treatment. Gingival crevicular fluid (GCF) has emerged as a valuable diagnostic medium because it reflects local inflammatory and metabolic changes occurring within periodontal tissues (8,9). Among the various biomarkers detected in GCF, matrix metalloproteinase-9 (MMP-9) has received considerable attention due to its critical role in extracellular matrix degradation and periodontal tissue remodeling (10).

Matrix metalloproteinases are a family of zinc-dependent endopeptidases involved in the breakdown of collagen and other extracellular matrix components during physiological and pathological processes. MMP-9, in particular, is secreted by inflammatory cells, osteoclasts, and fibroblasts in response to mechanical stress and inflammatory stimuli associated with orthodontic tooth movement (10). Experimental and clinical studies have demonstrated increased levels of MMP-9 in GCF during active orthodontic treatment, suggesting its involvement in bone remodeling and periodontal ligament turnover. Furthermore, elevated MMP-9 activity has been associated with osteoclastic activity and collagen degradation, processes that are closely related to the pathophysiology of root resorption (11,12).

Despite increasing evidence regarding the role of inflammatory mediators in orthodontic tooth movement, the relationship between MMP-9 levels in gingival crevicular fluid and the severity of orthodontically induced root resorption remains unclear. Additionally, limited clinical studies have compared biomarker responses between different orthodontic biomechanics, particularly in cases involving mini-implant-assisted intrusion and retraction of anterior teeth.

Therefore, the present prospective interventional study was designed to investigate the association between gingival crevicular fluid MMP-9 levels and the severity of orthodontically induced root resorption in patients undergoing orthodontic retraction of maxillary anterior teeth with or without mini-implant-assisted intrusion. The study aimed to evaluate longitudinal changes in MMP-9 levels at three standardized time points—before treatment (T0), at the initiation of retraction (T1), and three months after the start of retraction (T2)—and to correlate these changes with radiographically assessed root resorption.

Methods

This non-randomized control trial was approved by the Institutional Ethics Committee of MES Dental College on 02/05/2022 (IEC/MES/60/2022). The study was conducted in accordance with the

Declaration of Helsinki (2013) and registered with the Clinical Trials Registry of India (CTRI/2023/11/059918). Written informed consent was obtained from all participants or parents when they are under 18 years old, prior to enrollment.

Participants and Eligibility Criteria

Participants were recruited using a consecutive sampling method from patients attending the Department of Orthodontics at MES Dental College. The inclusion criteria were patients aged 14–30 years with Angle's Class I bimaxillary dentoalveolar protrusion requiring therapeutic extraction of first premolars in both jaws. Participants were required to have complete permanent dentition, excluding third molars, and no radiographic evidence of root resorption on OPG.

Patients were excluded if they had a history of previous orthodontic treatment or dental trauma, supernumerary teeth in the maxillary anterior region, impacted canines, endodontically treated teeth, upper anterior crowding ≥4 mm, or any systemic disease or medication history that could influence the study outcomes.

Participants were allocated into two groups according to the orthodontic mechanics employed:

- Group 1: Anterior retraction
- Group 2: Simultaneous intrusion and retraction (Figure 1)

This grouping was intended to determine whether differences in MMP-9 biomarker levels between groups could be attributed to orthodontically induced root resorption, as intrusive mechanics have been associated with an increased risk of root resorption (7,13).

Sample Size Estimation

Sample size estimation was performed using a standard deviation of 0.05, a two-sided significance level of 5%, and a statistical power of 90%. The expected mean difference of 0.097 was derived from previously published data (14).

Sample size was calculated using the formula

$$n = \frac{2(Z\alpha+Z1-\beta)^2 SD^2}{D^2}$$

- Zα (Value of Z at α error 5%) = 1.96
- Z1-β (Value of Z at β error 10%) = 1.282
- SD (Average standard deviation) = 0.05
- D (Difference between the means) = 0.097

Using these assumptions, the minimum required sample size was calculated to be 7 participants per group to detect a statistically significant difference between the groups. To account for potential attrition, additional participants were initially recruited. During the study period, two participants were lost to follow-up; however, the final analyzed sample consisted of 14 patients, with 7 participants in each group, which remained consistent with the calculated sample size required by the power analysis.

Participants were allocated to treatment groups based on their clinical characteristics. Patients presenting with a gummy smile requiring intrusion of the maxillary anterior teeth were assigned to the mini-implant–assisted intrusion and retraction group, whereas patients without a gummy smile underwent conventional anterior retraction. Therefore, random allocation was not feasible in this study.

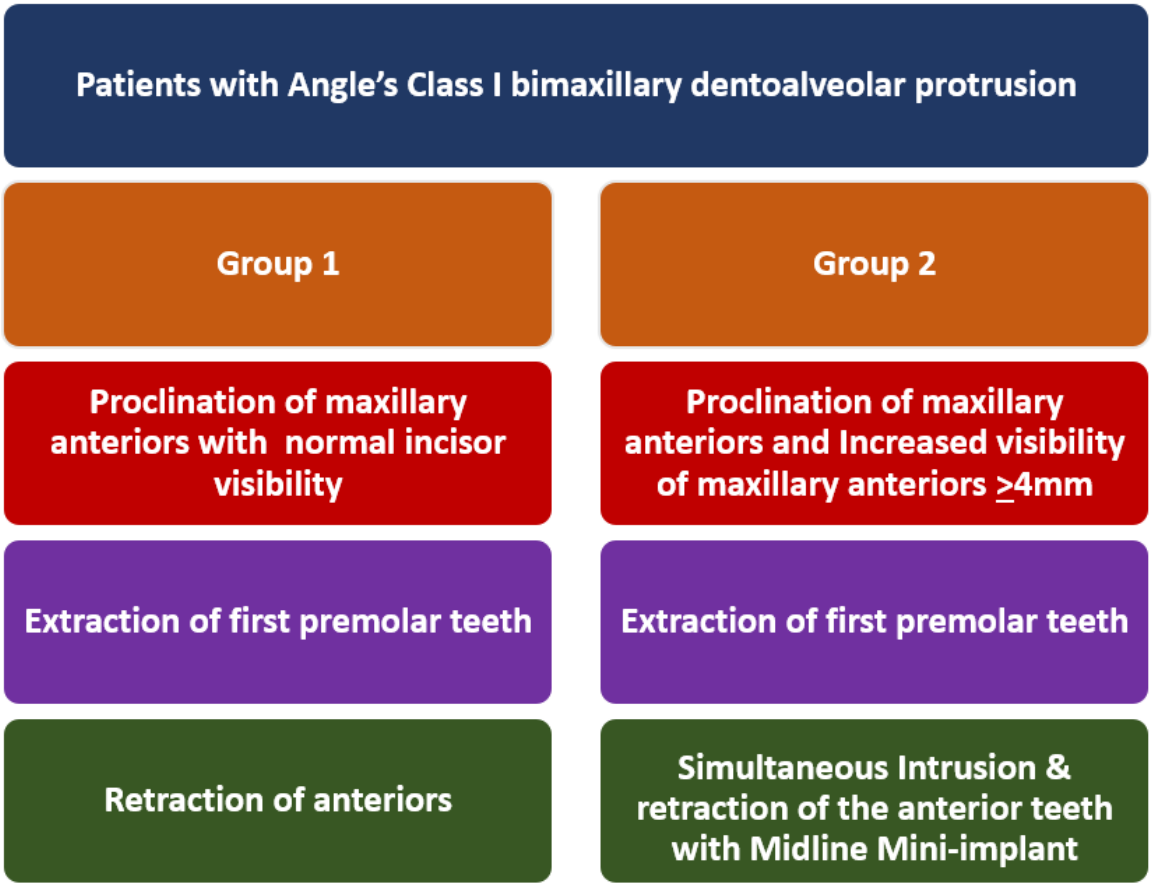

Figure 1: Classification of the study groups.

Orthodontic Treatment Protocol

All participants underwent orthodontic treatment using preadjused 0.022" MBT brackets (Ormco Mini 2000, Ormco, Glendora, USA) following extraction of four premolars. Bonding procedures were performed by a single operator to minimize inter-operator variability.

Alignment was initiated with 0.016" heat-activated nickel–titanium archwires, followed by 0.017" × 0.025" heat-activated NiTi and 0.019" × 0.025" heat-activated NiTi archwires (Ormco, Glendora, USA). Subsequently, 0.019" × 0.025" (Ormco, Glendora, USA) rectangular stainless steel archwires were used for en-masse retraction of the anterior teeth.

In Group 1, after the alignment and leveling phase, a 0.019 × 0.025-inch stainless steel archwire with hooks was placed in the bracket slots. The anterior teeth from canine to canine were ligated together using a ligature wire. Subsequently, a retraction force of 200 g using a Dontrix force gauge (Morelli, Brazil)was applied on each side using tie-backs attached to the hooks and molars bilaterally.

In Group 2, following the alignment and leveling phase, a 0.019 × 0.025-inch stainless steel archwire with hooks was inserted into the bracket slots and the anterior teeth from canine to canine were ligated. A self-drilling mini-implant (1.4 × 8 mm; Implant Genesis, JJ Orthodontics, India) was placed in the maxillary midline between the root apices of the central incisors, approximately 6–8 mm apical to the alveolar crest. An intrusive force of 60 g was delivered from the mini-implant to the midline of the archwire, along with a retraction force of 200 g on each side using tie-backs for anterior teeth retraction. Second molars were banded to reinforce anchorage. All procedures were carried out by the same investigator (Figure 2).

Professional oral prophylaxis was performed at baseline, and oral hygiene instructions were reinforced periodically throughout the study. Follow-up prophylaxis was provided during treatment visits to minimize periodontal inflammation. Although periodontal indices were not recorded, these preventive measures were applied uniformly across both groups to reduce

potential confounding effects on MMP-9 levels (15).

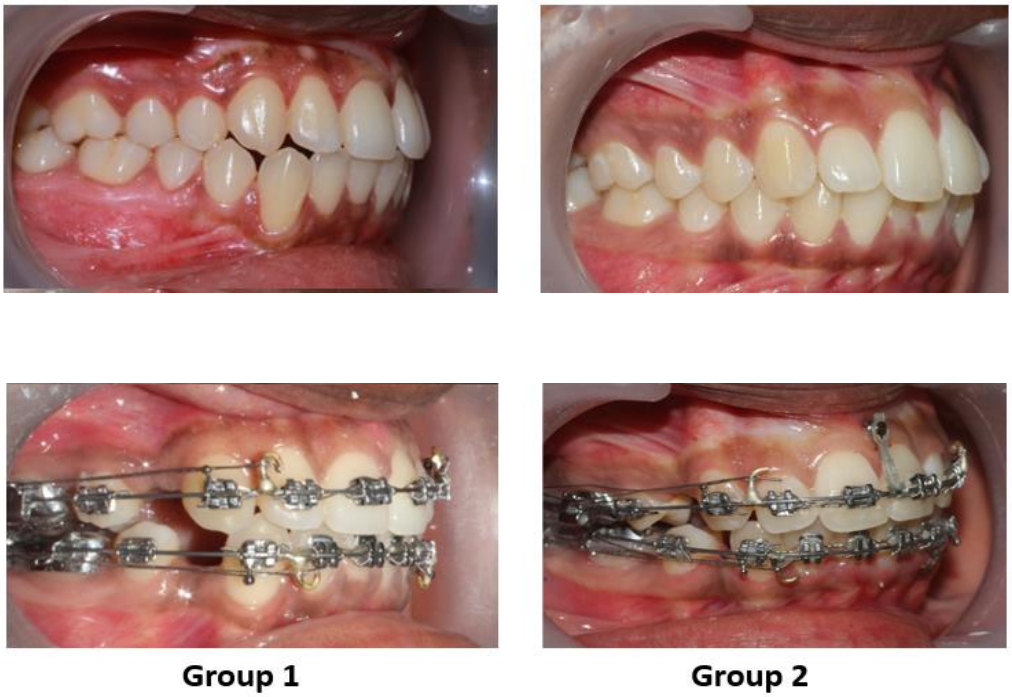

Figure 2: Intraoral photographs of Group 1 and Group 2 taken before treatment (above) and at the beginning of the study (below).

Gingival Crevicular Fluid Collection and Biomarker Analysis

GCF samples were collected from the maxillary incisors (FDI numbers #11, #12, #21, and #22). The teeth were isolated using cotton rolls, and PerioPaper strips (Oraflow Inc., Hewlett, New York, USA) were inserted into the mesiobuccal and distobuccal aspects of the gingival sulcus and left in place for 30 seconds. Strips contaminated with blood were excluded.

Following collection, the strips were placed in sterile Eppendorf tubes containing phosphate-buffered saline. Samples were centrifuged at 4°C for 10 minutes and stored at −20°C in the Department of Microbiology until further analysis.

Quantification of MMP-9 levels was performed using a 96-well sandwich enzyme-linked immunosorbent assay (ELISA) kit (Origin Diagnostics and Research, India) according to the manufacturer's instructions (Figure 3). The concentration of MMP-9 in each sample was determined by comparing the optical density values with the standard calibration curve (10).

Radiographic Assessment of Root Resorption

Digital intraoral periapical radiographs were obtained using an RVG-4 system (Trophy Radiologie S.A., Croissy-Beaubourg, France) with standardized exposure settings of 65 kVp, 8 mA, and 0.2 seconds. Radiographs were taken at predefined time points (Table 1) to evaluate root resorption before and after treatment (Figure 4).

The paralleling technique was used to maintain a consistent object–sensor distance and reduce image distortion. The pre-treatment RVG served as the reference image.

Apical root resorption was assessed using the Modified Malmgren Grading Criteria (13), which classifies resorption from grade 0 to grade 4 (Figure 5). Image analysis was performed using Adobe Photoshop (version 6.0; Adobe Systems), with images magnified to 300% without distortion to facilitate detailed evaluation.

Table 1: Sample collection time-points

	Time points	GCF	RVG
T0	Before treatment	✓	✓
T1	Beginning of retraction	✓	
T2	Three months after start of retraction	✓	✓



Figure 3: ELISA procedure.

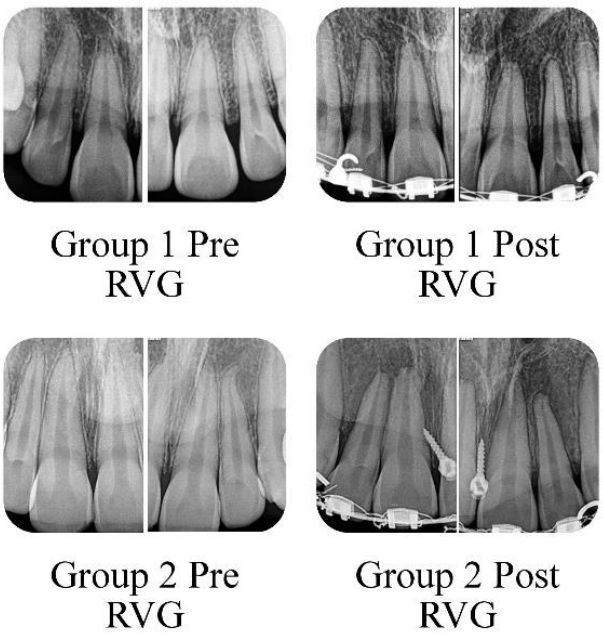

Figure 4: Pre and post-treatment radiographs of group 1 and group 2 patients at T_0 and T_2.

GRADE	FIGURE	DESCRIPTION
0		No root resorption
1		Mild resorption, root with normal length and irregular contour only
2		Moderate resorption with a small area of root loss and apex exhibiting an almost straight contour
3		Accentuated resorption with loss of almost one-third of root length
4		Extreme resorption with loss of more than one-third of root length

Figure 5: Index for assessing root resorption according to Modified Malmgren Grading criteria. (7)

Examiner Calibration and Reliability

To improve measurement reliability, the investigator responsible for radiographic evaluation underwent calibration prior to the assessment process. A subset of radiographs was re-evaluated after a two-week interval to assess intra-examiner reliability. The measurements showed good agreement, indicating acceptable reproducibility of the assessment method.

Blinding

Radiographic assessments were performed by a calibrated investigator using coded radiographic images. However, complete blinding was not feasible because the presence of mini-implants could be visible on some radiographs. To minimize potential observational bias, the evaluator was not informed about the study objectives or the treatment protocol during the assessment.

Statistical Analysis

All data were masked prior to statistical analysis and analyzed using SPSS version 26.0 (SPSS Inc., Chicago, IL, USA). Statistical significance was set at $P < 0.05$.

Descriptive statistics were used to calculate the mean and standard deviation for each group. The normality of the data distribution was assessed using the Shapiro–Wilk test. Independent t-test, Chi-Squared test and paired-test used for data analysis.

Results

The mean ages of patients in Group 1 and Group 2 were 18.28±2.65 and 19.85±1.64 years, respectively. Independent t-test indicated no significant difference in mean age between the two groups (P=0.71). Group 1 consisted of 3 males (42.8%) and 4 females (57.2%), while group 2 included 4 males (57.2%) and 3 females (42.8%). No statistically significant difference was observed in gender distribution based on Fisher's exact test (P=0.49) (Table 2).

Baseline MMP-9 levels were similar between the two groups, with mean values of 0.99±0.37 ng/mL for Group 1 and 0.96±0.10 ng/mL for Group 2, with no statistically significant difference (independent t-test, P>0.05). At T1, both groups exhibited a significant increase in MMP-9 levels (P=0.008). The highest mean MMP-9 levels were observed at T2 in both groups, with Group 1 at 2.12±0.49 ng/mL and Group 2 at 2.82±0.62 ng/mL, showing a statistically significant difference between the groups (independent t-test, P=0.03) (Table 3). The changes within Groups 1 and 2 across the different time points were statistically significant (P=0.0004 and P=0.0001, respectively).

Pre-treatment RVG at T0 did not reveal any root resorption in either group. Post-treatment RVG at T2 demonstrated a statistically significant increase

in root resorption within both groups, as assessed using the paired t-test (P=0.0001). The mean difference in root resorption grading was higher in Group 2 (1.35±0.49) compared to Group 1 (1.21±0.36); however, the difference between the two groups at T2 was not statistically significant (independent t-test, P=0.55) (Table 4).

The Pearson correlation plot for Group 1 (Figure 6) showed a moderate negative correlation between T2 MMP-9 values and T2 root resorption grade (Pearson r = -0.46, p = 0.299). In Group 2 (Figure 7), the Pearson correlation plot showed a strong negative correlation between T2 MMP-9 values and T2 root resorption grade (Pearson r = -0.89, p = 0.007).

Table 2: Demographic characteristics

	Group 1 (n=7)	**Group 2 (n=7)**	**Statistical test**	**P-value**
Gender				
Male	3(42.9)	4(57.1)		
Female	4(57.1)	3(42.9)		
Chi-Squared test			$\chi^2 = 0.56$	0.49
Age (year)	**Group 1 (Mean ± SD)**	**Group 2 (Mean ± SD)**	**Statistical test**	**P-value**
Independent t-test	18.28 ± 2.65	19.85 ± 1.64	t = 0.34	0.71

Table 3: Comparison of MMP-9 concentrations between groups

	Group 1(ng/ml)	**Group 2**(ng/ml)	**T-value**	**P-value**
T0	0.99±0.37	0.96±0.10	0.20	0.83
T1	1.40±0.41	2.01±0.30	3.17	0.008
T2	2.12±0.49	2.82±0.62	2.34	0.03
P-value	0.0004	0.0001		

T0: before treatment
T1: beginning of retraction
T2: three months after start of retraction

Table 4: Comparison of RVG Grading

		Group 1	**Group 2**	**T-Value**	**P-Value**
RVG Score	Pre-treatment	0	0	-	-
	Post-treatment	1.21±0.36	1.35±0.49	0.60	0.55
T-Value		8.89	9.78		
P-Value		0.0001	0.0001		

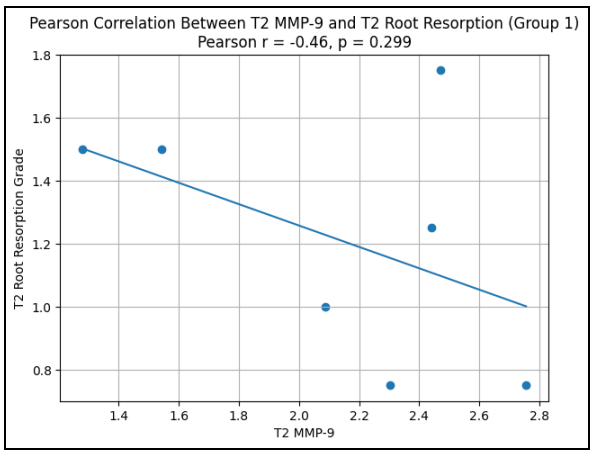

Figure 6: Pearson correlation plot for Group 1 between MMP-9 and grading of root resorption at T2

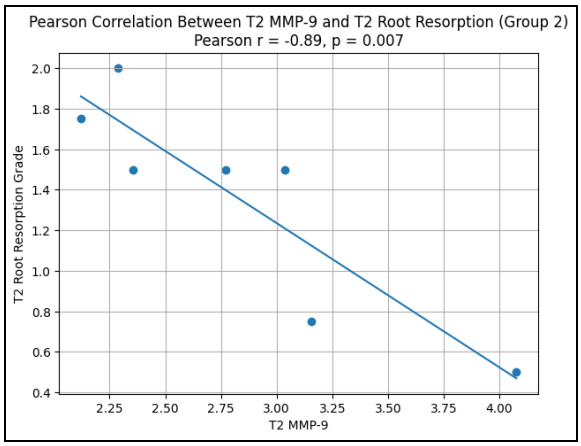

Figure 7: Pearson correlation plot for Group 2 between MMP-9 and grading of root resorption at T2

Discussion

The present study included patients with Angle's Class I malocclusion associated with bimaxillary protrusion, as this malocclusion type is commonly observed in the regional population. Bimaxillary protrusion is characterized by the forward positioning of both the maxillary and mandibular dentoalveolar segments and is often associated with proclined incisors, increased lip strain, and lip incompetence. The degree of protrusion is typically assessed using cephalometric parameters such as U1-NA (mm and degrees), U1-SN°, and incisor–lip relationships. In this study, these parameters were used during the initial screening to confirm the presence of bimaxillary protrusion and ensure appropriate patient selection.

Patient inclusion was based on a combination of clinical findings and cephalometric diagnosis, along with standardized criteria to maintain consistency in treatment protocols and minimize variability related to skeletal or dental patterns. Importantly, while cephalometric parameters guided patient selection, they were not the primary variables under investigation. Instead, the study focused on evaluating temporal changes in MMP-9 levels as a biomarker response to OIRR across various treatment phases. This methodological approach ensured that the primary objective remained central to the study.

The incidence and severity of OIRR remain unpredictable despite rapid advances in orthodontic techniques and materials, posing significant challenges for orthodontists in the non-surgical management of VME and gummy smile (16). Intrusion has been proposed as a potential initiator of root resorption among the various types of tooth movement (17,18). In recent years, there has been growing interest in identifying biomarkers associated with OIRR to enhance early detection, monitoring, and management. According to Taba et al. (19), a biomarker refers to a quantifiable biological parameter that indicates normal or pathological processes or therapeutic responses.

MMPs constitute a family of over 25 proteolytic enzymes that are vital for extracellular matrix degradation and remodeling (20). Among these biomarkers, MMP-9 has emerged as an important candidate due to its role in tissue remodeling and potential involvement in the pathogenesis of OIRR. MMP-9 levels significantly increase in osteoclasts during bone remodeling, and its expression can indicate active root resorption (12,21,22). Concurrently, dentin sialophosphoprotein (DSPP) prompts the secretion of the odontoblast regulatory factor RANKL, which subsequently fosters root resorption. Studies show that odontoclast activity during root resorption involves the cleavage of dentin sialophosphoprotein (DSPP) into two functional domains, dentin phosphoprotein (DPP) and dentin sialoprotein (DSP), by MMP-9 (21). Research has highlighted the upregulation of MMP-9 at sites of mechanical stress during orthodontic tooth movement, suggesting its potential as a non-invasive biomarker, given its presence and measurable activity in GCF (20-23). The current literature provides limited comparative data on MMP-9 as a biomarker for orthodontic root resorption, prompting its selection for this study.

Comparison of MMP-9 at T0 revealed no significant differences in MMP-9 levels between the

two groups. Both groups, however, showed significantly elevated MMP-9 levels at T2, with the highest levels in group 2. At both T1 and T2, Group 2 exhibited higher MMP-9 levels compared to Group 1, suggesting potentially increased OIRR. Over time, both Group 1 and Group 2 showed a progressive increase in MMP-9 levels from T0 to T2. This suggests that intrusion with midline mini-implants induces a more pronounced increase in MMP-9 levels, potentially reflecting enhanced root resorption, as there was no periodontal inflammation in the cohorts. In this regard, Ghaleb et al. (14) highlighted the potential of dentin phosphoprotein as a biomarker for monitoring root resorption during orthodontic treatment. Kereshanan et al. (24) investigated dentin DSP levels in GCF as a biomarker of root resorption and observed differences in DSP levels between patients undergoing orthodontic treatment and a control group, indicating the potential utility of DSP as a biomarker for detecting root resorption.

Additionally, Kunii et al. (25) measured IL-6 levels in GCF and found higher levels in patients with severe root resorption, suggesting a role for IL-6 in the resorptive process. Balducci et al. (26) observed higher concentrations of dentin matrix proteins in patients with root resorption, indicating a potential association between these proteins and the severity of root resorption. By comparing these findings with existing literature, we can infer the potential utility of MMP-9 as a biomarker for detecting OIRR and its implications for treatment planning and monitoring.

Advanced imaging techniques such as micro-CT and CBCT offer superior accuracy for three-dimensional assessment of root resorption (27,28). However, this study relied on two-dimensional RVG, as advanced modalities may not be routinely feasible in routine clinical practice due to non-availability, excessive radiation exposure, and cost considerations. While the use of the modified Malmgren grading in this study provides a qualitative assessment, it lacks the precision of direct measurements. Grading the root resorption from pre- and post-treatment RVGs of subjects in both groups revealed a statistically significant difference between the two time points (T0 and T2). These findings suggest that while there were no significant differences in RVG scores between the two groups before treatment, both groups experienced a significant change in RVG scores 3 months after retraction (T2), indicating active root resorption. This observation aligns with previous research by Linge and Linge (29), which suggests that intrusion may induce greater root resorption compared to overall orthodontic treatment. When comparing the present study with existing literature, it is crucial to consider differences in measurement techniques. While the present study used the modified Malmgren scores to assess root resorption, Vela-Hernández et al. (30) and Smale et al. (31) employed direct root length measurements before and after orthodontic treatment. Smale et al. (31) observed an average root resorption of 0.53 mm across four incisors, with a maximum of 4.4 mm. Vela-Hernández et al. (30) reported upper incisor resorption of 2.15±0.85 mm for group 1 (one miniscrew between upper central incisors) and 2.11±0.82 mm for group 2 (two miniscrews between upper lateral incisors and canines). Ohnishi et al. (32) also emphasized the significance of intrusion with mini-implants as a potential contributor to root resorption during orthodontic treatment. The Pearson correlation analysis revealed notable differences between the two groups in the relationship between MMP-9 levels and radiographic root resorption at T2. In Group 1, a moderate negative correlation was observed ($r = –0.46$), which was not statistically significant ($p = 0.299$). This finding suggests that although MMP-9 levels increased during the retraction phase, these biochemical changes did not necessarily correspond to radiographically detectable root resorption within the short observation period. It is possible that MMP-9 activation represents early matrix turnover that precedes clinically visible mineral loss, thereby limiting its correlation with RVG-based grading in this group.

In contrast, Group 2 demonstrated a strong and statistically significant negative correlation between T2 MMP-9 levels and root resorption grade ($r = –0.89$, $p = 0.007$). This pronounced inverse relationship may reflect the biological impact of combined intrusion and retraction forces, in which higher MMP-9 activity indicates active periodontal and dentin matrix remodeling, while early cemental or dentinal changes may remain below the detection threshold of two-dimensional radiography. The stronger correlation in Group 2 could therefore represent the heightened biological response associated with intrusive mechanics, despite the lack of a corresponding between-group difference in radiographic outcomes.

Overall, these correlation patterns support the concept that MMP-9 may serve as an early biomarker of tissue remodeling rather than a direct indicator of the severity of radiographically evident root resorption. The temporal mismatch between biochemical activity and radiographic detectability—combined with the limited sensitivity of the Modified Malmgren criteria—may

explain why elevated MMP-9 levels do not consistently parallel root resorption grade at this stage of treatment.

Limitations

Nevertheless, this study has several limitations that should be acknowledged. The relatively small sample size may limit the generalizability of the findings. In addition, root resorption was assessed using two-dimensional radiographic imaging rather than cone-beam computed tomography (CBCT), which may provide more precise three-dimensional evaluation of apical changes. The follow-up period was also relatively short, potentially limiting the ability to observe long-term changes in root morphology.

Despite these limitations, the results suggest that biomarker-based assessment may serve as a useful adjunct to conventional radiographic methods for the early detection of orthodontically induced root resorption (OIRR). Future studies with larger sample sizes and extended follow-up periods are needed to further clarify the role of MMP-9 in monitoring OIRR. Additionally, investigating MMP-9 in combination with other biomarkers may provide a more comprehensive understanding of the biological processes associated with orthodontic root resorption. Incorporating validated periodontal indices in future studies would also allow more accurate quantification and control of periodontal inflammation, thereby strengthening the interpretation of MMP-9 levels.

Conclusion

Both orthodontic retraction alone and retraction with mini-implant–assisted intrusion were associated with increases in GCF MMP-9 levels and mild radiographic root resorption over the three-month period. Although the intrusion group showed higher MMP-9 levels, this did not translate into clear radiographic differences between the groups. The study also noted a negative correlation between T2 MMP-9 levels and root resorption grade, suggesting that higher MMP-9 activity may occur alongside relatively limited radiographic changes at this early stage. However, the clinical importance of this observation remains uncertain, and additional research is needed to clarify its relevance.

Acknowledgements

The authors would like to acknowledge the support of the Department of Microbiology, MES Medical College, Perinthalmanna, Kerala, India.

Conflicts of Interest

There were no conflicts of interest.

Data Availability Statement

The data supporting the findings of this study are available from the corresponding author upon reasonable request.

Funding

This research received no external funding.

References

1. Vieira GM. Protein biomarkers of external root resorption: a new protein extraction protocol. Are we going in the right direction? Dental Press J Orthod. 2014;19(6):62-9. doi: 10.1590/2176-9451.19.6.062-069.oar.
2. Pereira ABN, Almeida R, Artese F, Dardengo C, Quintão C, Carvalho F. External root resorption evaluated by CBCT 3D models superimposition. Dental Press J Orthod. 2022;27(2):e2219315. doi: 10.1590/2177-6709.27.2.e2219315.oar.
3. Li Y, Zhang J, Wang L. Biological mechanisms and risk factors of orthodontically induced inflammatory root resorption: A contemporary review. Prog Orthod. 2023;24:38. doi: 10.1186/s40510-023-00489-5.
4. Singh P, Kaur H, Sharma N. Orthodontically induced root resorption: Current concepts in diagnosis, prevention and management. J Dent Sci. 2024;19(2):945-952. doi: 10.1016/j.jds.2023.10.016.
5. Tjan AH, Miller GD, The JG. Some esthetic factors in a smile. J Prosthet Dent. 1984;51(1):24-8. doi: 10.1016/s0022-3913(84)80097-9.
6. Zahrani AA. Correction of vertical maxillary excess by superior repositioning of the maxilla. Saudi Med J. 2010;31(6):695-702.
7. Levander E, Malmgren O. Evaluation of the risk of root resorption during orthodontic treatment: a study of upper incisors. Eur J Orthod. 1988;10(1):30-8. doi: 10.1093/ejo/10.1.30.
8. Chen Y, Li X, Zhou H. Clinical outcomes of mini-implant–assisted intrusion and retraction: a systematic review. Angle Orthod. 2023;93(6):732-741. doi: 10.2319/012623-072.1.

9. Al-Juboori MJ, Al-Huwaizi AF. Biomarkers in gingival crevicular fluid during orthodontic tooth movement: a systematic review. BMC Oral Health. 2023;23:742. doi: 10.1186/s12903-023-03485-8.
10. Park JH, Kim YK, Lee NK. Inflammatory biomarkers in gingival crevicular fluid during orthodontic tooth movement. Int J Mol Sci. 2024;25:2145. doi: 10.3390/ijms25042145.
11. Linsuwanont B, Takagi Y, Ohya K, Shimokawa H. Expression of matrix metalloproteinase-9 mRNA and protein during deciduous tooth resorption in bovine odontoclasts. Bone. 2002;31(4):472-8. doi: 10.1016/s8756-3282(02)00856-6.
12. Takahashi I, Onodera K, Nishimura M, Mitnai H, Sasano Y, Mitani H. Expression of genes for gelatinases and tissue inhibitors of metalloproteinases in periodontal tissues during orthodontic tooth movement. J Mol Histol. 2006;37(8-9):333-42. doi: 10.1007/s10735-006-9060-7.
13. Ramanathan C, Hofman Z. Root resorption in relation to orthodontic tooth movement. Acta Medica (Hradec Kralove). 2006;49(2):91. doi: 10.14712/18059694.2017.117.
14. Ghaleb S, Tamish N, ElKenany W, Guindi M. The effect of two different types of forces on possible root resorption in relation to dentin phosphoprotein levels: a single-blind, split-mouth, randomized controlled trial. Prog Orthod. 2021;22(1):44. doi: 10.1186/s40510-021-00388-y.
15. Francis PG, Parayaruthottam P, Antony V, Ummar F, Shaloob KMM, Hassan KJ. A comparative assessment of the effect of professional oral hygiene measures on the periodontal health of patients undergoing fixed orthodontic appliance therapy. J Indian Orthod Soc. 2019;53(1):43-8. doi: 10.4103/jios.jios_21_18.
16. Alexander SA. Levels of root resorption associated with continuous arch and sectional arch mechanics. Am J Orthod Dentofacial Orthop. 1996;110(3):321-4. doi: 10.1016/s0889-5406(96)80017-5.
17. Harry MR, Sims MR. Root resorption in bicuspid intrusion: a scanning electron microscope study. Angle Orthod. 1982;52(3):235-58. doi: 10.1043/0003-3219(1982)052<0235:RRIBI>2.0.CO;2.
18. Dermaut LR, De Munck A. Apical root resorption of upper incisors caused by intrusive tooth movement: a radiographic study. Am J Orthod Dentofacial Orthop. 1986;90(4):321-6. doi: 10.1016/0889-5406(86)90088-0.
19. Taba M, Kinney J, Kim AS, Giannobile WV. Diagnostic biomarkers for oral and periodontal diseases. Dent Clin North Am. 2005;49(3):551-71. doi: 10.1016/j.cden.2005.03.009.
20. Sekhon BS. Matrix metalloproteinases – an overview. Research and Reports in Biology. 2010:1:1-20. doi: https://doi.org/10.2147/RRB.S12043
21. Kyrkanides S, O'Banion MK, Subtelny JD. Nonsteroidal anti-inflammatory drugs in orthodontic tooth movement: metalloproteinase activity and collagen synthesis by endothelial cells. Am J Orthod Dentofacial Orthop. 2000;118(2):203-9. doi: 10.1067/mod.2000.105872.
22. Cantarella G, Cantarella R, Caltabiano M, Risuglia N, Bernardini R, Leonardi R. Levels of matrix metalloproteinases 1 and 2 in human gingival crevicular fluid during initial tooth movement. Am J Orthod Dentofacial Orthop. 2006;130(5):568-e11. doi: 10.1016/j.ajodo.2006.04.020.
23. Yuan G, Yang G, Song G, Chen Z, Chen S. Immunohistochemical localization of the NH2-terminal and COOH-terminal fragments of dentin sialoprotein in mouse teeth. Cell Tissue Res. 2012;349(2):605-14. doi: 10.1007/s00441-012-1418-4.
24. Kereshanan S, Stephenson P, Waddington R. Identification of dentine sialoprotein in gingival crevicular fluid during physiological root resorption and orthodontic tooth movement. Eur J Orthod. 2008;30(3):307-14. doi: 10.1093/ejo/cjn024.
25. Kunii R, Yamaguchi M, Tanimoto Y, Asano M, Yamada K, Goseki T, Kasai K. Role of interleukin-6 in orthodontically induced inflammatory root resorption in humans. Korean J Orthod. 2013;43(6):294-301. doi: 10.4041/kjod.2013.43.6.294.
26. Balducci L, Ramachandran A, Hao J, Narayanan K, Evans C, George A. Biological markers for evaluation of root resorption. Arch Oral Biol. 2007;52(3):203-8. doi: 10.1016/j.archoralbio.2006.08.018.
27. Chan EK, Darendeliler MA. Exploring the third dimension in root resorption. Orthod Craniofac Res. 2004;7(2):64-70. doi: 10.1111/j.1601-6343.2004.00280.x..
28. Dudic A, Giannopoulou C, Leuzinger M, Kiliaridis S. Detection of apical root resorption after orthodontic treatment by using panoramic radiography and cone-beam computed tomography of super-high resolution. Am J Orthod Dentofacial Orthop. 2009;135(4):434-7. doi: 10.1016/j.ajodo.2008.10.014.
29. Linge L, Linge BO. Patient characteristics and treatment variables associated with apical root resorption during orthodontic treatment. Am J Orthod Dentofacial Orthop. 1991;99(1):35-43. doi: 10.1016/S0889-5406(05)81678-6.
30. Vela-Hernández A, Gutiérrez-Zubeldia L, López-García R, García-Sanz V, Paredes-Gallardo V, Gandía-Franco JL, Lasagabaster-Latorre F. One versus two anterior miniscrews for correcting upper incisor overbite and angulation: a retrospective comparative study. Prog Orthod.

2020;21(1):34. doi: 10.1186/s40510-020-00336-2.
31. Smale I, Årtun J, Behbehani F, Doppel D, van't Hof M, Kuijpers-Jagtman AM. Apical root resorption 6 months after initiation of fixed orthodontic appliance therapy. Am J Orthod Dentofacial Orthop. 2005;128(1):57-67. doi: 10.1016/j.ajodo.2003.12.030.
32. Ohnishi H, Yagi T, Yasuda Y, Takada K. A mini-implant for orthodontic anchorage in a deep overbite case. Angle Orthod. 2005;75(3):444-52. doi: 10.1043/0003-3219(2005)75[444:AMFOAI]2.0.CO;2.