Iran J Orthod. 2026 June; 21(1):e1324. doi:10.22034/ijo.2026.2072930.1324.
Published online 2026 June 1 Research Article
Original Article **Open Access**

Investigating the Effect of Ultrasound on Preventing the Relapse of Severe Crowding : A Quasi- Experimental Clinical Trial

Arezoo Jahanbin [1], Neda Eslami [2], At-har Nasseri [3*], Afsaneh Zeinalzadeh [4], Mostafa Abtahi [2], Farnaz Ziya [5], Hooman Shafaee [2]

[1] Professor, Department of Orthodontics, School of Dentistry, Mashhad University of Medical Sciences, Mashhad, Iran
[2] Associate Professor, Department of Orthodontics, School of Dentistry, Mashhad University of Medical Sciences, Mashhad, Iran
[3] Assistant Professor, , Department of Orthodontics, School of Dentistry, Kerman University of Medical Sciences, Kerman, Iran
[4] Associate Professor, Department of Physical therapy, School of Paramedical and Rehabilitation Sciences, Mashhad University of Medical Sciences, Mashhad, Iran
[5] Assistant Professor, Department of Orthodontics, School Dentistry, Gilan University of Medical Sciences, Rasht, Iran
Medical Sciences, Mashhad, Iran

***Corresponding author:** At-har Nasseri

Address: Department of Orthodontics, School of Dentistry, Shafa Boulevard, Kerman, Iran

E-mail: nasseri.mojarad@gmail.com

Received: 2025 November 06; **Revised:** 2026 May 14; **Accepted:** 2026 February 17

Abstract

Aim
Orthodontic relapse after alignment remains a major clinical concern. This study aimed to evaluate whether adjunctive low-intensity ultrasound could reduce the rate of orthodontic relapse and improve post-treatment stability compared with no intervention.

Methods
In this quasi-experimental clinical trial, 39 patients (mean age 19.3 ± 5.7 years) with Class I malocclusion and severe dental crowding were enrolled after completion of alignment. Participants were randomly allocated to an ultrasound group (n = 20) or a control group (n = 19). The ultrasound group received therapeutic ultrasound (EME, Pesaro, Italy) at 1 MHz, 100 mW/cm², 20% duty cycle (200 µs on/800 µs off; 1000 cycles/s), for 10 min/session over 10 sessions. In both groups, archwires were then removed for 2 months; the control group received no additional intervention. Dental casts were obtained at archwire removal (baseline) and after 2 months. Outcomes were inter-canine width, inter-molar width, arch length, arch circumference, and modified Little's irregularity index. Analyses used Chi-square, independent t-test, and paired t-test with $\alpha = 0.05$.

Results
All 39 participants were included in the analyses. Over 2 months, between-group differences in changes of inter-canine width, inter-molar width, arch length, arch circumference, and modified Little's irregularity index were not statistically significant (P > 0.05). In both groups, modified Little's irregularity index differed significantly between the maxilla and mandible (ultrasound: P = 0.025; control: P = 0.002). Within-group analysis showed a significant reduction in mandibular arch circumference in the ultrasound group (P = 0.007) and a significant increase in maxillary arch circumference in the control group (P = 0.018).

Conclusion
Under the conditions of this trial, low-intensity ultrasound did not reduce orthodontic relapse in the maxilla or mandible during the 2-month post-alignment period.

Keywords: Orthodontic retention, Relapse, Ultrasound.

Copyright © 2026, Author(s). This is an open-access article distributed under the terms of the Creative Commons Attribution-NonCommercial 4.0 International License (http://creativecommons.org/licenses/by-nc/4.0/) which permits copy and redistribute the material just in noncommercial usages, provided the original work is properly cited.

Background

Orthodontic relapse, defined as the tendency of teeth to return toward their pretreatment position following orthodontic therapy, remains one of the most significant challenges in orthodontic practice (1–3). Despite considerable advancements in orthodontic biomechanics and treatment protocols, achieving long-term stability continues to be difficult. Several biological and mechanical factors have been implicated in relapse, including periodontal and gingival fiber reorganization, occlusal interferences, soft-tissue pressures from the lips and tongue, and continued craniofacial growth (1–4). Consequently, retention strategies are routinely implemented after orthodontic treatment; however, relapse can still occur even with prolonged retention (2,3).

In recent years, increasing attention has been directed toward adjunctive approaches aimed at improving orthodontic treatment outcomes and enhancing post-treatment stability. Various modalities have been investigated, including pharmacologic agents, surgical adjuncts, low-level laser therapy, mechanical vibration devices, and ultrasound-based technologies (5–8). Among these, low-intensity pulsed ultrasound (LIPUS) has attracted considerable interest because of its non-invasive nature and its potential biological effects on bone and soft-tissue remodeling (9,10).

Ultrasound produces both thermal and non-thermal biological effects. The non-thermal effects, such as acoustic streaming and cavitation, can enhance cell membrane permeability, stimulate cellular signaling pathways, and promote tissue regeneration. These mechanisms have been widely investigated in orthopedic research, where LIPUS has been shown to stimulate bone formation, enhance fracture healing, and improve soft-tissue repair (9–11). The ability of ultrasound to influence bone metabolism has led researchers to explore its potential applications in orthodontics.

Several experimental and clinical studies have suggested that LIPUS may influence orthodontic tooth movement and bone remodeling. Laboratory studies have demonstrated that LIPUS can stimulate osteoblastic differentiation, increase the expression of osteogenic markers, and enhance bone formation in periodontal tissues (12–15). These biological effects may facilitate more efficient bone remodeling around the tooth-supporting structures during orthodontic treatment.

Beyond its potential effects on tooth movement, LIPUS has also been investigated as an adjunct to functional orthodontic therapy and other orthodontic procedures. Clinical studies have reported that the application of LIPUS during functional treatment of skeletal Class II malocclusion may contribute to improvements in sagittal skeletal relationships through enhanced mandibular adaptation (16). In addition, studies evaluating the use of LIPUS with clear aligner therapy have reported increases in alveolar bone radiodensity, suggesting enhanced bone remodeling activity (17). Experimental studies have also demonstrated that LIPUS may stimulate bone regeneration following rapid maxillary expansion by promoting new bone formation within the midpalatal suture (18).

Despite these promising findings, the clinical effectiveness of LIPUS in orthodontics remains controversial. Some randomized clinical trials have reported no significant acceleration of orthodontic tooth movement or reduction in treatment-related discomfort with the adjunctive use of LIPUS (19,20). Furthermore, recent systematic reviews and meta-analyses have concluded that although LIPUS demonstrates encouraging biological effects in experimental models, the current clinical evidence regarding its effectiveness in accelerating orthodontic tooth movement, preventing root resorption, or improving treatment outcomes remains limited and inconsistent (21,22).

In recent years, some researchers investigated the biological and clinical effects of ultrasound in orthodontics. These studies suggest that it may influence cellular signaling pathways involved in bone remodeling and periodontal ligament response, potentially affecting orthodontic tooth movement and post-treatment stability. Nevertheless, further well-designed clinical trials are still required to clarify its clinical efficacy and to determine optimal treatment protocols for orthodontic applications (23–25).

So, the current study evaluated the influence of ultrasonic radiation on relapse prevention in dental arches in patients undergoing fixed orthodontic treatment.

Methods

This study was designed as a quasi-experimental clinical trial with two parallel groups. Patients were recruited between 2022 and 2024 at the Department of Orthodontics, Mashhad University of Medical Sciences. They had a mean age of 19.3 ± 5.7 years and presented with Class I malocclusion and severe dental crowding (>8 mm space deficiency). All patients were undergoing fixed orthodontic treatment with 0.022-inch MBT

appliances following extraction of the four first premolars.

The patients had completed the aligning and leveling stage, and no visible crowding or rotation was present in the dental arches.

The study was conducted in accordance with the ethical principles of the Declaration of Helsinki and the Guidelines for Biomedical and Health Research Involving Human Participants (2017) of the Iranian Council of Medical Sciences. Ethical approval was obtained from the Institutional Ethics Committee (IR.MUMS.DRC.REC.1401.21; dated May 28, 2022). The trial was also registered in the Iranian Registry of Clinical Trials (IRCT20221028056331N1). Written and verbal informed consent was obtained from all participants prior to enrollment in the study. For participants under 18 years of age, consent was obtained from their parents or legal guardians.

Patients with systemic problems, poor oral hygiene, gingivitis or periodontal problems, deep caries spreading to the cementoenamel junction, taking drugs affecting bone metabolism, and conditions for which ultrasound is contraindicated, such as pregnancy, the presence of a malignant lesion in the area exposed to radiation, etc., were excluded.

As no comparable studies were identified in the literature to guide sample size estimation, the calculation was performed based on an assumed effect size. Considering a significance level of 0.05 (95% confidence interval) and a statistical power of 80%, and assuming an effect size (f) of 0.88, the minimum required sample size was calculated to be 16 participants per group using the following formula:

$N = 2(Z_{1-\alpha/2} + Z_{1-\beta})^2 / f^2$

To compensate for a possible dropout rate of approximately 15%, the sample size was increased to 20 participants in each group.

So, in this investigation, 42 patients (31 females and 11 males) were selected.

Participants were recruited using a convenience sampling method from patients who were undergoing orthodontic treatment at the Department of Orthodontics. Due to the requirement for repeated attendance for ultrasound therapy sessions, group allocation was performed based on the patients' availability and willingness to attend the intervention sessions. Accordingly, patients who were able to regularly attend the ultrasound sessions were allocated to the intervention group, while those who were not able to attend these sessions were assigned to the control group. Because of the nature of this quasi-experimental design, randomization and allocation concealment were not performed.

Due to the nature of the intervention, blinding of the participants and the operator was not possible. However, the outcome assessor who performed the measurements on the dental casts was blinded to the group allocation to minimize measurement bias.

Finally, the study groups in the present investigation were defined as follows:

Control group: In this group, the archwire was removed from both arches, and the initial impression (T0) was taken using alginate (Alginate Chromogel, Iran Marlic, Iran). The patients did not receive any special intervention for two months. The impressions were poured with orthodontic plaster (S Hinridur, Type 3, Germany) to prepare the first casts. After two months, a secondary impression (T1) was taken by alginate and study model was prepared.

Intervention group: In the intervention group , the patients received ultrasound treatment (EME ,Pesaro , Italy) with a frequency of 1 MHz, an intensity of 100 mW/cm2, a duty cycle of 20% (200 on-us and 800 off-us in 1000 cycles per second), for 10 minutes per session for 10 sessions. Ultrasound gel (Polygel, PalizTeb Company, Iran) was applied to the target area, covering the canines, alveoli, and arches to facilitate device movement and wave passage.

The ultrasound device was applied to the back of the patient's lips, teeth, and gums with an intensity >30 mW/cm2 to account for attenuation in lip tissue. The device used in this study had a minimum intensity of 100 mW/cm2, falling within the typical range of 30–150 mW/cm2 for physical therapy devices (12).

In the majority of thermal and non-thermal applications, ultrasound is typically applied for 5–10 minutes per treatment area, with an effective radiating area (ERA) of 2.

The device head was placed in contact with the tissue, and treatment was initiated by pressing the start button after ensuring proper contact. The applicator was then moved in an oval motion to cover the entire lip area. This procedure was performed for 10 sessions on alternate days (Figure 1). After treatment, the archwires were removed, and an initial alginate impression was made(T0). Patients remained without archwires for two months, followed by secondary impression(T1) and casting with orthodontic plaster.

To assess relapse, all casts were positioned at a fixed vertical distance from a stationary camera (Nikon D90, Japan) mounted on a tripod at 25 cm distance to ensure proper focus. A measuring gauge

was placed alongside the casts to aid in measuring the magnification of the images . Subsequently, the images of the casts were transferred to a computer and analyzed using ImageJ software (Rasband, W.S., ImageJ, U. S. National Institutes of Health, Bethesda, Maryland, USA) to measure parameters considering magnification before and after the intervention in both groups. In the ImageJ software, the Line Tool was selected from the toolbar to set the scale, and a line was drawn along measuring gauge on each digital cast. Next, the Set Scale window was opened through Analyze > Set Scale. At this stage, the actual length of guage was entered in the Known Distance field. The unit "mm" was also entered in the Unit of Length field. After confirming these settings, the image scale was converted to real units, and all subsequent measurements were performed based on this calibrated scale.

1. Inter-canine width: It is the distance (mm) between the cusp tip of one canine and the cusp tip of the contralateral canine in the dental arch.



Figure 1. The patient receiving ultrasonic waves in the canine-to-canine region.

2. Inter-molar width: The distance (mm) between the mesiobuccal cusp tips of the first molars on both sides of the dental arch(Figure 2).

3. Arch length: The perpendicular distance (mm) from the line connecting the mesial marginal ridges of the right and left first molars to the contact point between the central incisors (Figure 3).

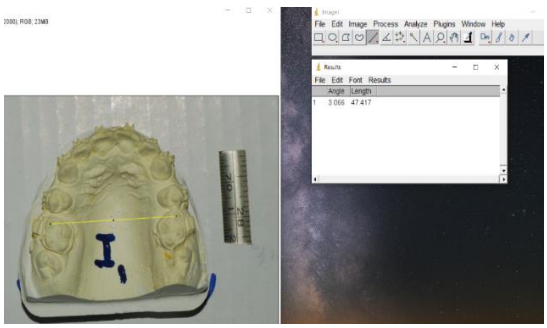

Figure 2. Measurement of inter-molar width using ImageJ software with magnification correction**.**

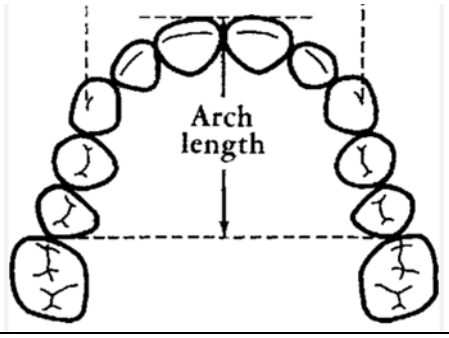

Figure 3. Arch length**.**

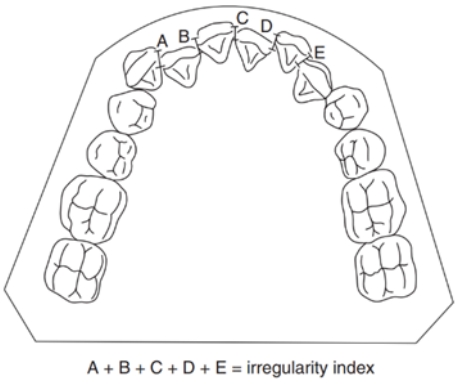

Figure 4. Modified Little's irregularity index.

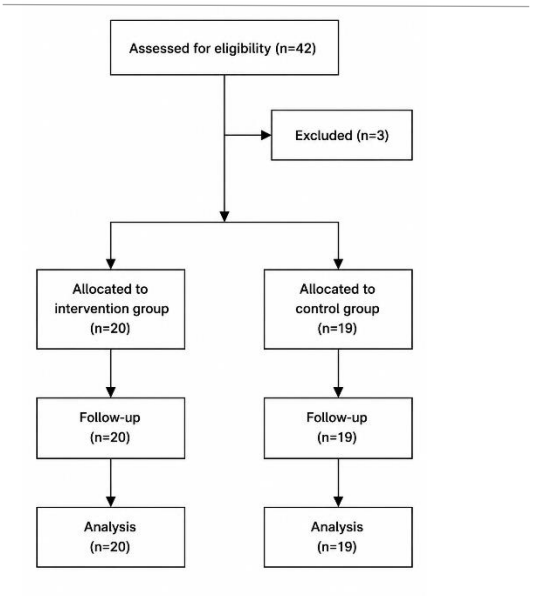

Figure 5. CONSORT flow diagram of participant selection and allocation

4. Arch circumference: Provided in millimeters and is measured as the extent along a line that passes via the central fossa on posterior teeth, as well as via the cingulum present on the anterior teeth within the upper arch. Also, a specific line passing between the tips of the posterior buccal cusps, as well as an incisal edge on the anterior tooth in the lower arch, is included.

5. Modified Little's irregularity index: In each dental arch, the distance (mm) between the interdental contact points of adjacent teeth in the canine-to-canine region was measured. The five measured distances were then summed to obtain the total index (Figure 4).

However, two participants in the control group and a participant who was incorporated in the intervention group were excluded throughout the study for specific reasons; this exclusion was a result of the fact that these participants failed to show up for their scheduled follow-ups. Based on the above exclusions, the study was carried out with 39 patients (control group: 19, intervention group: 20) who continued participating. (Figure 5)

Statistical analysis was performed using SPSS software, version 26.0 (IBM Corp., Armonk, N.Y., USA). Data normality was evaluated using the Kolmogorov–Smirnov test. Given the normal distribution of the data, Chi-Squared test, paired and independent t-tests were used for data analysis. A p-value of less than 0.05 was considered statistically significant.

Results

There were 39 patients in this clinical trial, including 28 females and 11 males, aged 13–34 years, with a mean age of 19.3 ± 5.7 years. According to Table 1, the mean age as well as sex distribution, was not significantly different between the groups.

Table 2 shows the means and standard deviations of inter-molar widths in maxilla and mandible for intervention and control groups. Statistical analysis showed no significant differences in inter-molar width of both groups in the upper and lower arches (P>0.05). Similarly, paired t-test analysis revealed no significant differences in inter-molar width before treatment (T0) and after treatment (T1) in the upper and lower jaws for both groups (P>0.05).

Table 3 presents the means and standard deviations of inter-canine widths in both the upper and lower jaws for intervention and control groups at T0 and T1. The independent t-test showed no significant variations in inter-canine width alterations between the two groups (P>0.05). Correspondingly, paired t-test analysis also affirmed no significant differences in inter-canine width before treatment (T0) and after treatment (T1) in both the upper and lower jaws for groups (P>0.05).

Table 4 presents the means and standard deviations of arch length for the maxilla and mandible in the control and intervention groups at various time intervals. Paired t-test revealed no statistically significant pre- and post-treatment changes in arch length in either the upper or lower jaws for the control group. A significant reduction in arch length was, however, recorded in the mandible of the intervention group following ultrasonic exposure (P=0.035). This finding is despite the changes in the maxillary arch of the intervention group, which were not statistically significant. The independent t-test demonstrated no significant differences in arch length between the two groups (P>0.05).

Table 1: Demographic characteristics

Variable	Control group	Intervention group	Total
Number of patients (n)	19	20	39
Female, n (%)	16(84.22)	12(60)	28 (71.8%)
Male, n (%)	3(15.78)	8(40)	11 (28.2%)
Chi-Squared test			P = 0.093
Mean age (years) ± SD	18.89 ± 3.92	19.70 ± 7.10	19.3 ± 5.7
Independent t-test			P = 0.068

Table 2: Comparison of mean and standard deviation of inter molar width of both groups at T0 and T1 in maxilla and mandible

Inter molar width		Intervention group (mm)		Control group (mm)		The result of independent
		Mean	SD	Mean	SD	T-test
	T0	49.822	3.125	50.720	2.866	P = 0.357
Max	T1	49.994	3.232	50.979	2.383	P = 0.288
	T1-T0	0.171	2.009	0.258	1.564	P = 0.881
Paired T- test result		P = 0.707		P = 0.480		
	T0	43.936	2.691	45.036	3.578	P = 0.283
Man	T1	43.834	3.043	44.714	2.662	P = 0.344
	T1-T0	- 0.101	1.743	- 0.321	3.554	P = 0.806
Paired T- test result		P = 0.798		P = 0.698		

Table 3: Comparison of mean and standard deviation of inter canine width of both groups at T0 and T1 in maxilla and mandible

Inter canine width		Intervention group (mm)		Control group (mm)		The result of independent
		Mean	SD	Mean	SD	T-test
	T0	36.575	2.656	36.937	2.728	P = 0.671
Max	T1	36.009	2.576	36.241	2.189	P = 0.764
	T1-T0	-0.565	1.275	-0.693	2.252	P = 0.824
Paired T- test result		P = 0.062		P = 0.194		
	T0	28.609	1.710	28.466	1.773	P = 0.799
Man	T1	27.829	1.955	27.804	1.938	P = 0.968
	T1-T0	- 0.780	1.727	- 0.622	1.429	P = 0.818
Paired T- test result		P = 0.058		P = 0.058		

Table 4: Comparison of mean and standard deviation of arch length of both groups at T0 and T1 in maxilla and mandible

Arch length		Intervention group (mm)		Control group (mm)		The result of independent
		Mean	SD	Mean	SD	T-test
	T0	37.116	2.360	36.463	2.646	P = 0.421
Max	T1	30.502	2.061	36.578	2.229	P = 0.462
	T1-T0	-6.614	1.523	0.115	1.464	P = 0.787
Paired T- test result		P = 0.966		P = 0.735		
	T0	31.012	1.947	30.962	3.578	P = 0.957
Man	T1	30.502	2.061	30.840	3.045	P = 0.686
	T1-T0	- 0.51	2.711	- 0.122	3.381	P = 0.981
Paired T- test result		P = 0.035		P = 0.892		

Table 5 presents the means and standard deviations of arch circumferences in the maxilla and mandible for control and intervention groups. Paired t-test indicated no significant differences in arch circumferences in the upper jaw for the intervention group or in the lower jaw for the control group (P>0.05). A significant reduction in mandibular arch circumference was, however, identified in the intervention group (P=0.007), while a significant increase in maxillary arch circumference was identified in the control group (P=0.018). Independent t-test results indicated no significant difference between the two groups in terms of arch circumference (P>0.05).

Table 6 shows the means and standard deviations for modified Little's irregularity index before and after intervention in the upper and lower jaws for each group. The independent t-test showed no significant difference in the irregularity index of both jaws between intervention and control groups at T0 and T1 (P>0.05). However, according to paired t- test, there were statistically significant difference between maxilla and mandible for intervention (P=0.025) and control (P=0.002) groups.

Table 5: Comparison of mean and standard deviation of arch circumference of both groups at T0 and T1 in maxilla and mandible

Arch circumference		Intervention group (mm)		Control group (mm)		The result of independent
		Mean	SD	Mean	SD	T-test
	T0	90.897	5.598	90.451	5.362	P = 0.801
Max	T1	90.443	4.751	91.932	5.420	P = 0.367
	T1-T0	-0.454	3.535	1.481	2.476	P = 0.056
		P = 0.572		P = 0.018		
	T0	81.827	4.191	82.255	7.195	P = 0.821
Man	T1	80.128	4.286	82.317	6.500	P = 0.220
	T1-T0	- 1.699	4.606	0.062	6.589	P = 0.804
Paired T- test result		P = 0.007		P = 0.972		

Table 6: Comparison of mean and standard deviation of Modified little's irregularity index of both groups at T0 and T1 in maxilla and mandible

Modified little's irregularity index		Intervention group (mm)		Control group (mm)		The result of independent
		Mean	SD	Mean	SD	T-test
	T0	4.422	2.577	3.840	1.775	P = 0.419
Max	T1	5.528	2.464	4.996	1.828	P = 0.426
	T1-T0	1.105	2.442	1.125	2.257	P = 0.979
Paired T- test result		P = 0.057		P = 0.043		
	T0	3.442	1.170	3.308	1.393	P = 0.746
Man	T1	4.535	1.553	4.526	1.256	P = 0.985
	T1-T0	1.093	2.004	1.218	1.492	P = 0.827
Paired T- test result		P = 0.025		P = 0.002		

Discussion

Orthodontic relapse remains one of the most significant challenges in orthodontic treatment, even after successful alignment and correction of malocclusion. Despite the use of various retention strategies, a certain degree of relapse is frequently observed following the removal of orthodontic appliances. The present clinical study aimed to evaluate whether the application of ultrasonic radiation could reduce relapse in patients with severe dental crowding after completion of orthodontic alignment. The findings of this study indicated that the application of ultrasound did not significantly influence most of the evaluated dental arch parameters, including inter-molar width, inter-canine width, arch length, arch circumference, and the modified Little's irregularity index, when compared with the control group during the two-month observation period. These results suggest that the ultrasonic protocol used in this investigation was not effective in preventing early orthodontic relapse. Relapse tendencies were observed in both groups during the follow-up period. In particular, the modified Little's irregularity index increased significantly in the mandibular arch of both groups and in the maxillary arch of the control group, indicating a degree of

post-treatment crowding recurrence. Orthodontic tooth movement is the result of an inflammatory process caused by sterile necrosis. This process results from the conversion of orthodontic forces into biochemical reactions, which form the basis for inducing the simultaneous differentiation of bone-forming and bone-resorbing cells. Consequently, teeth move within the remodeled bone and periodontal tissues (26). The rate of orthodontic tooth movement depends on the remodeling of alveolar bone, and the limiting factor for tooth movement is bone resorption at the interface between bone and the periodontal ligament. Macrophages, odontoclasts, and osteoclasts are the cells involved in the removal of necrotic tissue in the hyalinized area. This process mainly leads to resorption of mineralized tissue through the secretion of tartrate-resistant acid phosphatase (TRAP), cathepsin-K, and matrix metalloproteinase-9 (MMP-9) (14, 27-29). It has been shown that low-intensity ultrasound has a biostimulatory effect on osteoblasts and osteoclasts. In addition, LIPUS has been shown to increase the number of cells and cellular activities within the PDL, which may play an important role in alveolar bone remodeling. (30,31) The mechanical stimulation generated by LIPUS is detected by cell membrane receptors such as integrins (14, 32) and G-protein-coupled receptors (GPCRs) (33), which activate various mechanotransduction pathways in bone cells. This leads to increased gene expression (34, 35), which in turn results in increased protein expression(14). In osteoblasts, LIPUS increases the expression of osteogenic proteins such as RUNX2 (Runt-related transcription factor 2) (36), osteoprotegerin (37), and alkaline phosphatase (38). Ultrasound has various physical effects that can be divided into thermal and non-thermal effects. Therapeutic ultrasound generally has a frequency between 0.7 and 3.3 MHz to maximize energy absorption at a depth of 2 to 5 cm in soft tissue (39). In most thermal and non-thermal applications, ultrasound should be applied for 5–10 minutes for each treatment area with a surface area approximately twice the effective radiating area (ERA) of the transducer (40). Therefore, in our study, an average time of 10 minutes was considered appropriate. It has been reported that the stimulatory effect of LIPUS is dose-dependent. It has also been determined that daily intraoral use of LIPUS for 20 minutes per day for six months can be beneficial in accelerating tooth movement (41,42). The findings of the present study support the latter observations, suggesting that the clinical impact of ultrasound on orthodontic relapse may be limited under the conditions tested. One possible explanation for the absence of a significant preventive effect in this study may be related to the duration and frequency of ultrasound application. Previous investigations have suggested that the biological response to LIPUS is highly dependent on treatment parameters such as intensity, duration, and cumulative exposure (43,44). In many orthopedic and bone-healing studies, ultrasound stimulation is applied daily over extended periods to achieve measurable biological effects. In contrast, the present study included a limited number of ultrasound sessions prior to archwire removal, which may not have been sufficient to influence long-term periodontal and alveolar bone remodeling. Furthermore, orthodontic relapse is widely recognized as a multifactorial phenomenon. In addition to alveolar bone remodeling, relapse is influenced by periodontal ligament fiber reorganization, gingival and transseptal fiber elasticity, occlusal forces, soft tissue pressures from the lips and tongue, and continued craniofacial growth. Because of these multiple contributing factors, interventions that primarily affect bone metabolism alone may not be sufficient to prevent relapse. Some methodological factors should also be considered when interpreting the results. Differences in bone density, periodontal ligament responsiveness, and patient-specific remodeling rates may affect the biological response to mechanical stimulation such as ultrasound. In addition, attenuation of ultrasonic energy through soft tissues during external application may reduce the effective dose reaching periodontal structures (45). Within the limitations of this clinical trial, the application of ultrasonic radiation did not demonstrate a significant preventive effect on early orthodontic relapse in patients with severe crowding. Further randomized controlled trials with larger sample sizes, longer follow-up periods, and optimized ultrasound protocols are required to clarify whether ultrasound may have a meaningful adjunctive role in orthodontic retention strategies.

Limitations

Several limitations of the present study should be acknowledged when interpreting the results. First, the relatively small sample size may limit the statistical power and generalizability of the findings. Recruitment of a larger cohort was challenging due to the time-consuming nature of the intervention protocol and the need for repeated patient cooperation throughout the study period. Furthermore, ethical considerations regarding the control group—particularly the absence of additional therapeutic benefit despite

extended participation—limited the feasibility of prolonging the follow-up duration. Another limitation was the unequal gender distribution, with approximately two-thirds of the participants being female. Although this may reflect the higher proportion of female patients seeking orthodontic treatment in clinical practice, the imbalance may restrict the ability to fully evaluate potential sex-related differences in relapse patterns. In addition, digital intraoral scanning technology was not available to the research team at the time of data collection. As a result, measurements were performed on dental casts obtained from conventional impressions. Nevertheless, all impressions, cast preparations, and measurements were carried out under standardized conditions and with careful calibration in order to minimize measurement error.

Conclusion

Within the limitations of this clinical study and the relatively short two-month observation period, the application of ultrasonic radiation did not demonstrate a statistically significant effect on reducing early orthodontic relapse in either the mandibular or maxillary arches. While the biological rationale for ultrasound stimulation in bone remodeling is supported by experimental evidence, the clinical benefits for relapse prevention were not clearly demonstrated under the conditions evaluated in this study. Therefore, the use of ultrasonic radiation as an adjunctive method for preventing orthodontic relapse cannot be recommended based solely on the present findings. Future randomized controlled trials with larger sample sizes, balanced gender distribution, longer follow-up periods, and optimized ultrasound parameters are needed to better clarify the potential clinical role of ultrasound in orthodontic retention and post-treatment stability.

Acknowledgments

We would like to thank Mrs. Ziba Shirkhani for her assistance in statistical analysis.

Conflict of Interests

The authors declare that they have no conflicts of interest.

Data Availability Statement

The data that support the findings of this study are available upon request from the corresponding author.

Funding

Vice Chancellor for Research of Mashhad University of Medical Sciences

**The authors used ChatGPT version 4.0 for English editing of the manuscript.

References

1. Littlewood SJ, Kandasamy S, Huang G. Retention and relapse in clinical practice. Aust Dent J. 2017;62 Suppl 1:51-57. doi: 10.1111/adj.12475.
2. Littlewood SJ, Millett DT, Doubleday B, Bearn DR, Worthington HV. Retention procedures for stabilizing tooth position after treatment with orthodontic braces. Cochrane Database Syst Rev.2016;2016(1):CD002283. doi: 10.1002/14651858.CD002283.pub4.
3. Al Yami EA, Kuijpers-Jagtman AM, van 't Hof MA. Stability of orthodontic treatment outcome: follow-up until 10 years postretention. Am J Orthod Dentofacial Orthop. 1999;115(3):300-4. doi: 10.1016/s0889-5406(99)70333-1.
4. Johnston CD, Littlewood SJ. Retention in orthodontics. Br Dent J. 2015 ;218(3):119-22. doi: 10.1038/sj.bdj.2015.47.
5. Fleming PS, Fedorowicz Z, Johal A, El-Angbawi A, Pandis N. Surgical adjunctive procedures for accelerating orthodontic treatment. Cochrane Database Syst Rev. 2015;2015(6):CD010572. doi: 10.1002/14651858.CD010572.pub2.
6. Levy M. Cyclic loading (vibration) accelerates tooth movement in orthodontic patients: A double-blind, randomized controlled trial. 2015, 21(3): 187-194. doi:10.1053/J.SODO.2015.06.005
7. Xue H, Zheng J, Chou MY, Zhou H, Duan Y. The effects of low-intensity pulsed ultrasound on the rate of orthodontic tooth movement. Semin Orthod 2015; 21(3): 219-223. doi: 10.1053/j.sodo.2015.06.009.
8. Cokakoglu S, Akgun FA, Aydin B. Low-level laser therapy in orthodontics. Meandros Med Dent J. 2018;19(2):99-105. doi:10.1590/2177-6709.22.6.094-101.bbo
9. Zhao B, Yu Q, Lv M, Song J, Liu T, et al. The biological effects of low intensity pulsed ultrasound in osteoblasts. Transl Med (Sunnyvale) . 2018; 8(1): 200. doi:

10.4172/2161-1025.1000200.
10. Griffin XL, Parsons N, Costa ML, Metcalfe D. Ultrasound and shockwave therapy for acute fractures in adults. Cochrane Database Syst Rev. 2014 ;2014(6):CD008579. doi: 10.1002/14651858.CD008579.pub3.
11. Padilla F, Puts R, Vico L, Raum K. Stimulation of bone repair with ultrasound: a review of the possible mechanic effects. Ultrasonics. 2014;54(5):1125-45. doi: 10.1016/j.ultras.2014.01.004.
12. Pascoal S, Monteiro F, Oliveira S, Simoni A, Carvalho Ó, Pinho T. Biomodulation effects induced by ultrasound stimulation in periodontal cells implicated in orthodontic tooth movement: A systematic review. Orthod Craniofac Res. 2025;28(1):54-66. doi: 10.1111/ocr.12845.
13. Lim K, Kim J, Seonwoo H, Park SH, Choung PH, Chung JH. In vitro effects of low-intensity pulsed ultrasound stimulation on the osteogenic differentiation of human alveolar bone-derived mesenchymal stem cells for tooth tissue engineering. Biomed Res Int. 2013;2013:269724. doi: 10.1155/2013/269724.
14. Al-Daghreer S, Doschak M, Sloan AJ, Major PW, Heo G, Scurtescu C, Tsui YY, El-Bialy T. Effect of low-intensity pulsed ultrasound on orthodontically induced root resorption in beagle dogs. Ultrasound Med Biol. 2014;40(6):1187-96. doi: 10.1016/j.ultrasmedbio.2013.12.016.
15. Higashi Y, Inami K, Shimizu H, Matsumoto N. Effect of low intensity pulsed ultrasound on osteoclast differentiation. Orthod Waves. 2020 ;79(4):163-9. doi: 10.1080/13440241.2020.1843354.
16. Almrayati B, Alhazmi A, Aldrees AM, et al. Evaluation of low-intensity pulsed ultrasound during functional orthodontic treatment in Class II malocclusion. J Orthod. 2022;49(3):284-292. doi:10.1177/14653125211051262.
17. Al-Dboush R, Esfahani AN, El-Bialy T. Impact of photobiomodulation and low-intensity pulsed ultrasound adjunctive interventions on orthodontic treatment duration during clear aligner therapy. Angle Orthod. 2021;91(5):619-625. doi: 10.2319/112420-956.1.
18. Erkan E, Karaçay Ş, Çikler E, Polat İÖ. Evaluation of in vivo effects of low-intensity pulsed ultrasound and low-level laser therapy on premaxillary suture during rapid maxillary expansion. Turk J Orthod. 2025 ;38(4):233-243. doi: 10.4274/TurkJOrthod.2025.2025.79.
19. Farzanegan F, Bamrood Z, Rangrazi A, Shafaee H. Effect of ibuprofen and low-intensity pulsed ultrasound on the reduction of pain after initial archwire placement: a double-blind randomized clinical trial. J Oral Res. 2022; 11(1): 1-12. doi:10.17126/joralres.2022.001.
20. Yadav S, Dobie T, Assefnia A, Gupta H, Kalajzic Z, Nanda R. Effect of low-frequency mechanical vibration on orthodontic tooth movement. Am J Orthod Dentofacial Orthop. 2015;148(3):440-9. doi: 10.1016/j.ajodo.2015.03.031.
21. Shahri A, Kazemi H, Bardideh E, Bahadorani Z. Efficacy of low-intensity pulsed ultrasound in orthodontic tooth movement and pain perception in human studies: a systematic review and meta-analysis. BMC Oral Health. 2026;26(1):512. doi: 10.1186/s12903-026-07888-5.
22. Zhao Y, Su Q, Zhang B, Xia K, Zhao L, Zhao Z. Efficacy of low-intensity pulsed ultrasound in orthodontic tooth movement and orthodontically induced root resorption in animal and human studies: a systematic review and meta-analysis. Clin Oral Investig. 2024 ;29(1):6. doi: 10.1007/s00784-024-06096-1.
23. Wei Y, Guo Y. Clinical applications of low-intensity pulsed ultrasound and its underlying mechanisms in dentistry. App Sci. 2022 ;12(23):11898. doi:10.3390/app122311898.
24. Sorout S, Jnaneshwar P, Kannan R. Effect of low-intensity pulsed ultrasound on the duration of mandibular anterior crowding correction and pain perception in adults undergoing orthodontic treatment: a single-blinded randomized control trial. Dental Press J Orthod.2025;30(1):e2524158. doi: 10.1590/2177-6709.30.1.e2524158.oar.
25. Qin YX. Ultrasound imaging and regulated mechanotransduction for characteristics, regeneration, and therapeutics of bone. Mechanobiol Med. 2025 ;3(1):100116. doi: 10.1016/j.mbm.2025.100116.
26. Huang H, Williams RC, Kyrkanides S. Accelerated orthodontic tooth movement: molecular mechanisms. Am J Orthod Dentofacial Orthop. 2014;146(5):620-32. doi: 10.1016/j.ajodo.2014.07.007.
27. Li Y, Jacox LA, Little SH, Ko CC. Orthodontic tooth movement: The biology and clinical implications. Kaohsiung J Med Sci. 2018;34(4):207-214. doi: 10.1016/j.kjms.2018.01.007.
28. Krishnan V, Davidovitch ZE, Kuijpers-Jagtman AM. Biological orthodontics. In: Krishnan V, Davidovitch ZE, Kuijpers-Jagtman AM, editors. Biological mechanisms of tooth movement. third edition, Hoboken, Wiley and Blackwell;2021. P:217-37.
29. Ferguson DJ, Vaid NR, Wilcko MT. Assessing accelerated tooth movement techniques on their own catabolic merits: a review. J World Fed Orthod. 2018 ;7(4):122-7.doi: 10.1016/j.ejwf.2018.11.003.
30. de Lucas B, Pérez LM, Bernal A, Gálvez BG. Ultrasound therapy: experiences and perspectives for regenerative medicine. Genes (Basel). 2020 ;11(9):1086. doi: 10.3390/genes11091086.

31. Watabe H, Furuhama T, Tani-Ishii N, Mikuni-Takagaki Y. Mechanotransduction activates $\alpha_5\beta_1$ integrin and PI3K/Akt signaling pathways in mandibular osteoblasts. Exp Cell Res. 2011 ;317(18):2642-9. doi: 10.1016/j.yexcr.2011.07.015.
32. Xia P, Wang X, Qu Y, Lin Q, Cheng K, Gao M, Ren S, Zhang T, Li X. TGF-β1-induced chondrogenesis of bone marrow mesenchymal stem cells is promoted by low-intensity pulsed ultrasound through the integrin-mTOR signaling pathway. Stem Cell Res Ther. 2017
33. Vansant L, Cadenas De Llano-Pérula M, Verdonck A, Willems G. Expression of biological mediators during orthodontic tooth movement: A systematic review. Arch Oral Biol. 2018;95:170-186. doi: 10.1016/j.archoralbio.2018.08.003.
34. Fávaro-Pípi E, Bossini P, de Oliveira P, Ribeiro JU, Tim C, Parizotto NA, Alves JM, Ribeiro DA, Selistre de Araújo HS, Renno AC. Low-intensity pulsed ultrasound produced an increase of osteogenic genes expression during the process of bone healing in rats. Ultrasound Med Biol. 2010 ;36(12):2057-64. doi: 10.1016/j.ultrasmedbio.2010.07.012.
35. Yang Z, Ren L, Deng F, Wang Z, Song J. Low-intensity pulsed ultrasound induces osteogenic differentiation of human periodontal ligament cells through activation of bone morphogenetic protein-smad signaling. J Ultrasound Med. 2014;33(5):865-73. doi: 10.7863/ultra.33.5.865.
36. Akagi H, Nakanishi Y, Nakanishi K, Matsubara H, Hirose Y, Wang PL and Ochi M. Influence of low-intensity pulsed ultrasound stimulation on expression of bone-related genes in rat bone marrow cells. J Hard Tissue Biol. 2016, 25: 1–5. doi:10.2485/jhtb.25.1 [4].
37. Inubushi T, Tanaka E, Rego EB, Ohtani J, Kawazoe A, Tanne K, Miyauchi M, Takata T. Ultrasound stimulation attenuates resorption of tooth root induced by experimental force application. Bone. 2013;53(2):497-506. doi: 10.1016/j.bone.2013.01.021.
38. Shaw A, ter Haar G, Haller J, Wilkens V. Towards a dosimetric framework for therapeutic ultrasound. Int J Hyperthermia. 2015 Mar;31(2):182-92. doi: 10.3109/02656736.2014.997311.
39. Katta RC, Chava VK, Nagarakanti S. Supportive periodontal therapy-a review. Ann Essenc Dent. 2016 ;8(1): 1-11. doi: 10.5368/aedj.2016.8.1.3.1.
40. Conner-Kerr T, Oesterle ME. Current perspectives on therapeutic ultrasound in the management of chronic wounds: a review of evidence. Chronic Wound Care Manage Res. 2017 ; 4:89-98.doi: 10.2147/CWCMR.S135982.
41. El-Bialy T, Farouk K, Carlyle TD, Wiltshire W, Drummond R, Dumore T, Knowlton K, Tompson B. Effect of low intensity pulsed ultrasound (LIPUS) on tooth movement and root resorption: a prospective multi-center randomized controlled trial. J Clin Med. 2020 ;9(3):804. doi: 10.3390/jcm9030804.
42. Badiee M, Tehranchi A, Behnia P, Khatibzadeh K. Efficacy of low-intensity pulsed ultrasound for orthodontic pain control: a randomized clinical trial. Front Dent. 2021 ;18:38. doi: 10.18502/fid.v18i38.7607.
43. Maurya RK, Jayan B, Singh H, Nakra O, Sharma P. Effects of low-intensity pulsed ultrasound therapy on the temporomandibular joint complex in conjunction with a fixed functional appliance: a prospective 3-dimensional cone beam computed tomographic study. J Ultrasound Med. 2019;38(7):1661-1676. doi: 10.1002/jum.14850.
44. Jahanbin A, Farzanegan F, Mashreghi A, Raisolsadat SM, Hoseini Zarch H, Mostafaee N. Is low intensity pulsed ultrasound (LIPUS) effective in the success rate of alveolar cleft graft? J Pediatr Perspect. 2022 ;10(12):17093-102. doi:10.22038/ijp.2022.66844.5008
45. Abeas KA, Al-Azawy AM. Immunohistochemical evaluation of osteocalcin expression with application of LIPUS during relapse phase of orthodontic therapy. J University Babylon. 2017;25(2):620-629.