



# A Roentgenographic Comparative Investigation of The Midpalatal Suture Obliteration Evidenced Through Occlusal and Cone Beam CT Radiographs

Pratheesh A P <sup>1</sup>, Deepu Leander <sup>2</sup>, Ranjana Ravindran <sup>3\*</sup>, Ravindran Ankathil <sup>4</sup>

<sup>1</sup> Assistant Professor, PMS College of Dental Science and Research, Kerala University of Health Sciences, Thiruvananthapuram, India

<sup>2</sup> Professor, PMS College of Dental Science and Research, Kerala University of Health Sciences, Thiruvananthapuram, India

<sup>3</sup> Assistant Professor, Sri Sankara Dental College, Kerala University of Health Sciences, Thiruvananthapuram, India

<sup>4</sup> Chief Scientist, PMS College of Dental Science and Research, Kerala University of Health Sciences, Thiruvananthapuram, India

\* Corresponding Author: Ranjana Ravindran

Address: Sri Sankara Dental College, Vattappara, Thiruvananthapuram, India

Email: rravindran282@gmail.com

Received: 2024 February 13; Revised: 2024 April 17; Accepted: 2024 May 16

## Abstract

**Background:** Assessing the midpalatal suture (MPS) maturation is crucial to successfully predict rapid maxillary expansion. Therefore, radiographic measurement of the suture width is vital for treatment planning. This study compared MPS ossification using cross-sectional maxillary occlusal radiographs and cone-beam computed tomography (CBCT) scans to aid clinicians in making better treatment decisions.

**Methods:** In this study, 33 patients were selected as the study cohort and were categorized into two distinct groups according to their chronological age. Group I included individuals in the growth phase, aged between 8 to 16 years, while Group II encompassed post-adolescent and young adult participants aged between 16 to 25 years. The percentage of MPS ossification was calculated using the suture obliteration index calculated on axial cross-sectional images. Statistical analysis was performed utilizing the student t-test with a significance level set at 0.05.

**Results:** No significant difference was found between occlusal radiographs and CBCT scans in the assessment of MPS ossification in the anterior part ( $P>0.05$ ). However, significant differences existed in the suture obliteration index in anterior part ( $P=0.031$ ) and posterior part ( $P=0.035$ ), with higher mean values obtained by occlusal radiographs. In contrast, significant differences favoring CBCT were found in the anterior part ( $P<0.001$ ) with higher mean values; no significant difference was found in the posterior part. Lastly, significant difference did not exist in the posterior part between the two imaging modalities ( $P>0.05$ ).

**Conclusion:** For MPS assessment, both CBCT and occlusal radiography can provide predictable results. However, it is notable that CBCT still has an upper hand in providing better and more accurate results.

**Keywords:** Cone-Beam Computed Tomography, Cranial Sutures, Hard Palate, Radiography

## Background

Facial sutures are the key mediators of skeletal adaptation to craniofacial growth and

biomechanical treatments (1). The midpalatal suture (MPS) is an end-to-end suture that starts from the posterior part of the palatomaxillary suture and extends longitudinally to the



nasopalatine foramen in the palatal bone (2,3). Among the existing cranial sutures, the MPS in human beings is the only suture that could possibly remain open in aged patients.

It is estimated that about 23.3% transverse maxillary deficiency exists in the primary dentition and is much higher in the permanent dentition (4, 5). Ever since Angell, in his pioneering work around 160 years ago (in 1860) presented the theory that the maxilla can be increased by opening the MPS (6), controversy developed in the orthodontic literature from 1860-1930 raising the question of whether the hard palate at the MPS could be widened. Rapid maxillary expansion (RME) through opening the MPS is exceedingly beneficial in both surgical and nonsurgical treatments of class III cases, specifically benefitting non-surgical cases of maxillary deficiency (both true and relative), cases of inadequate nasal capacity with chronic nasal respiratory problems, mature cleft palate patients, and a selection of arch length problems frequently accompanying tooth extraction (7). Chronological age is counted as an essential factor for opting between RME and surgically assisted RME (SARME)/Le Fort osteotomy to treat maxillary deficiency. To date, the decision of whether to use SARME has been an age-based one (8). Substantial amount of distinctive variability is detected in MPS maturation (9), and it has been reported that MPS commences fusion and obliteration as early as adolescence, possibly staying evident until the third or fourth decade of life when a considerable degree of MPS maturation and obliteration is predicted (10,11). Angelieri et al. (12) in 2013 introduced the MPS morphology classification method wherein he divided the maturation stages dichotomously into A–C and D or E, possibly assisting in eluding the side effects of RME failure or unnecessary SARME.

A decrease in the MPS width due to age and functional factors occurs, that can impact resistance to rapid maxillary expansion (RME) (8). For this reason, radiographic evidence to visualize and measure MPS width is crucial for treatment planning. Revelo and Fishman (13) in 1994 proposed a method to individually analyze MPS development by occlusal radiography. However, the overlapping imageries in 2D radiography cause challenges in evaluating them because the superimposition of the vomer and external nose structures may possibly cause erroneous radiographic interpretations. An exclusive assessment method for evaluating the maturation of the midpalatal suture (MPS), as proposed by Angelieri et al. in 2013, utilizes cone beam computed tomography (CBCT) scans. This approach aids in determining the suture's maturation level

prior to any intervention. Unlike occlusal radiographs, CBCT scans provide a volumetric image of the oral and maxillofacial structures, enabling the isolation of the MPS area without superimposition of other anatomical structures.

The treatment of maxillary constriction in the transverse plane is a challenging field for orthodontists, which is notably true in post-adolescent and young adult patients because of the lack of agreement in the existing literature concerning the correct timing for expansion, and wide variations have been seen in MPS ossification pattern.

Hence, this study aimed to evaluate and compare two imaging techniques, namely maxillary occlusal radiography and CBCT, by evaluating their efficacy in determining the percentage of MPS ossification. It also aimed to evaluate whether there was any agreement regarding MPS ossification between CBCT and occlusal radiography and if there was any difference in the stages of MPS ossification between CBCT and occlusal radiography.

## Methods

In the present study, two different imaging systems (CBCT and occlusal radiography) were compared for assessment of MPS ossification in patients with maxillary transverse deficiency. The age group of the study participants was selected according to the recommendations of Revelo and Fishman (13). They observed that MPS ossification was present at merely 50% by the end of skeletal maturation, and midpalatal approximation occurred more posteriorly during all of the adolescence period. Persson and Thilander (11) found that broad variations existed in different parts of the suture in the same individuals, and in the degree of closure between subjects of the same group.

With a confidence level of 95%, power of 80%, and precision of 15%, the sample size was calculated to be 27. To increase the validity of the study, the sample size was increased to 33. Thirty-three patients were categorized into two groups based on their chronological age. Group I comprised of individuals in the growing age group between 8 to 16 years, while group II comprised of post-adolescents and young adults between 16 to 25 years. Group II was further subdivided into two subgroups: subgroup 1 (16.1 to 20.0 years) and subgroup 2 (20.1 to 25.0 years). This subdivision was motivated by Revelo and Fishman's findings (13), indicating a significant correlation between growth completion and MPS ossification initiation,

with considerable inter-individual variations in the ossification process. Angelieri et al, (12) also noted substantial morphological variations in the suture among patients over 20 years of age. The patients were selected based on the criteria stated in Table 1.

The diagnostic tools used were maxillary occlusal radiographs and CBCT scans of the maxilla. The midpalatal suture (MPS) was observed as a dark

radiolucent line running between the roots of the central incisors and reaching the posterior palate. If there was no clear radiolucency between the dense cortical linings, it indicated ossification of the MPS.

The visualization and categorization of the skeletal maturation stage of the MPS were carried out following the technique outlined by Angelieri et al. (12), as shown in Figures 1 and 2.

Table 1. Inclusion and exclusion criteria	
Inclusion criteria	Exclusion criteria
1. Patients in the age group of 8 to 25 years and without any obvious craniofacial abnormalities	1. Patients with a history of orthodontic treatment
2. Patients who were willing to participate in the study and gave written informed consent	2. Patients with cleft lip and palate
3. Patients with moderate to severe transverse maxillary constriction in the form of a narrow V-shaped maxillary arch with deep palatal vault and or posterior crossbite	3. Patients with osteoporosis, endocrine disorders, or syndromic conditions

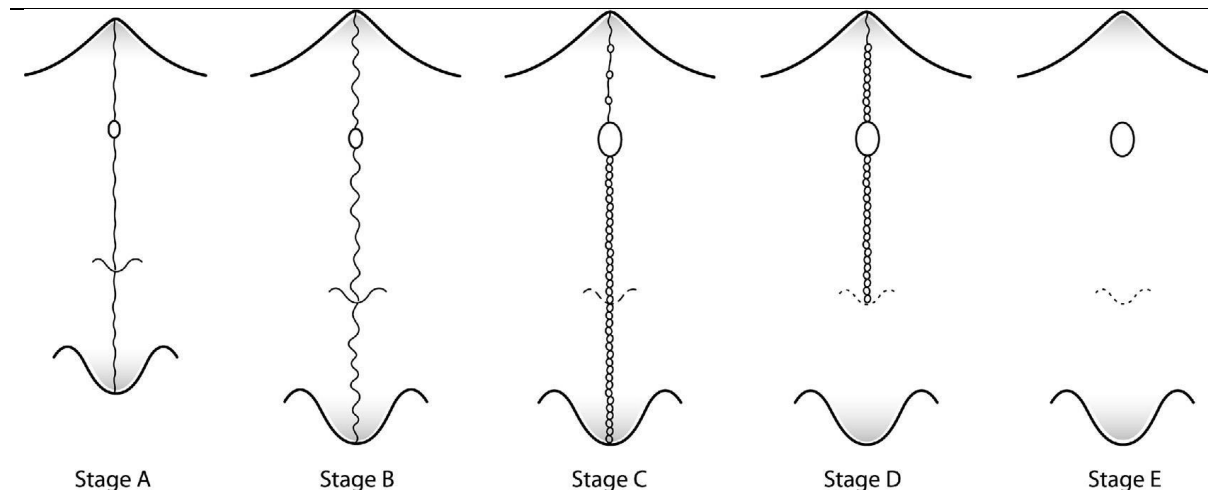
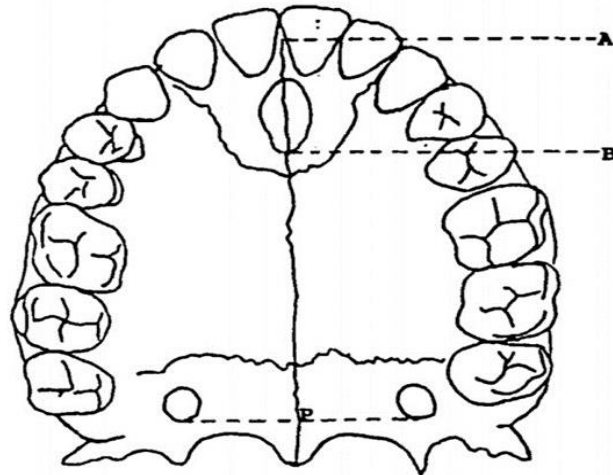


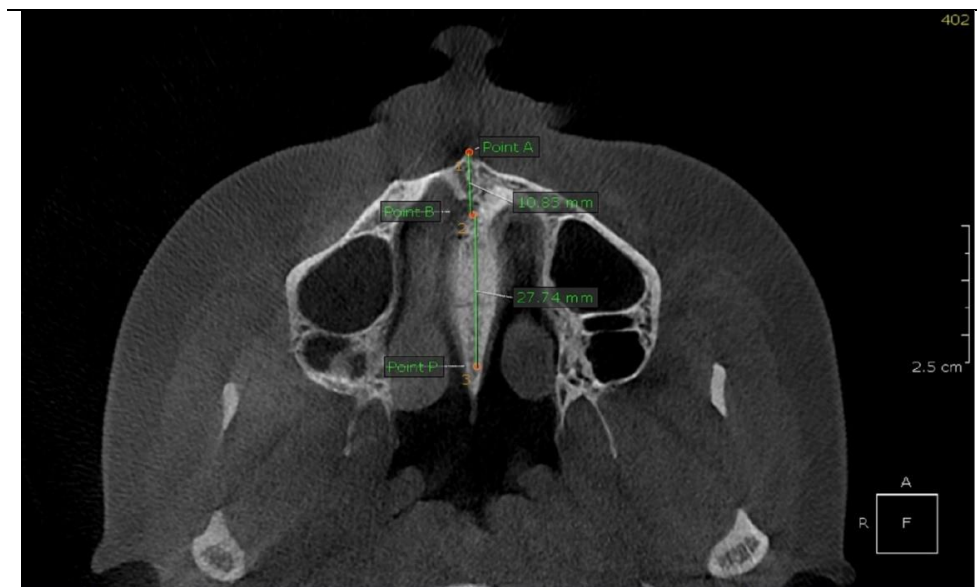Figure 1. Maturation stages of MPS

Stage A: straight lines with high density, Stage B: sutural lines with high density and toothed edge, Stage C: two sutural lines with high density and parallel to each other and little distance from each other, Stage D: complete ossification without observation of the suture line, and Stage E: complete ossification of the maxillary bone.



**Figure 2.** Anatomical landmarks

Point A: Most anterior point of the premaxilla. Point B: Most posterior point on the posterior wall of the incisive foramen. Point P: The point of intersection between the MPS line and a line tangent to the posterior surface of permanent maxillary second molars. A–B: Anterior part, B–P: Posterior part



**Figure 3.** Midpalatal suture ossification in CBCT

Two oral and maxillofacial radiology experts, with extensive training in identification of radiographic landmarks, conducted the calibrations. All MPS images were classified by two blinded expert examiners in a dark room, following Angelieri et al.'s maturational stages (12). Then the identical procedure was carried out by the same examiners on occlusal radiographs.

#### ***Cross-sectional Maxillary Occlusal Radiographs***

Maxillary occlusal radiographs were taken from each patient using intraoral occlusal films. The occlusal radiographs were traced on acetate tracing papers.

#### ***Calculation of suture obliteration index***

Axial cross-sections were used to calculate the suture obliteration index. A line was drawn from the anterior nasal spine to the posterior nasal spine.

First, the overall length of the suture and then the length of the ossified segment were measured, and the obliteration index was calculated using the following formula:

The suture obliteration index was calculated separately for the anterior and posterior parts. The same formula was used for calculation of the percentage of ossification of the MPS using CBCT.

**Statistical analysis**

Data were entered into a Microsoft Excel datasheet and analyzed using SPSS software version 17.0 (SPSS Inc., Chicago, USA). Continuous

data were presented as mean and standard deviation. The student t-test was used to compare the variables. The intra-class correlation coefficient (ICC) was used for inter-examiner reliability assessment. ICC values less than 0.5 were indicative of poor reliability, values between 0.5 and 0.75 indicated moderate reliability, values between 0.75 and 0.9 indicated good reliability, and values greater than 0.90 indicated excellent reliability (15). P<0.05 was considered statistically significant.

$$\text{Suture obliteration index} = \frac{\text{Length of MPS ossified} \times 100}{\text{Total length of the suture}}$$

**Results**

According to Table 2, on cross-sectional occlusal radiographs of group I patients, inter-examiner reliability using ICC was found to be 0.956 indicating excellent reliability between the examiners. The inter-examiner reliability using ICC was found to be 0.943 for CBCT indicating excellent reliability between the examiners.

As shown in Table 3, on cross-sectional occlusal radiographs of group II patients, there was no difference between examiner 1 and examiner 2, as all observations were the same. The inter-examiner reliability using ICC was determined to be 0.890 for CBCT, indicating good reliability between the examiners.

Examiner reliability in group I between cross-sectional occlusal radiographs and CBCT scans was calculated using ICC, which was determined to be 0.579, indicating moderate reliability in examiner 1. Examiner reliability between cross-sectional occlusal radiographs and CBCT scans was calculated using ICC, which was found to be 0.669, indicating moderate reliability in examiner 2 (Table 4).

In group II, the examiner reliability between cross-sectional occlusal radiographs and CBCT scans was calculated using ICC, which was found to be 0.636, indicating moderate reliability for examiner 1. The examiner reliability between cross-sectional occlusal radiographs and CBCT scans was calculated using ICC, which was found to be 0.573, indicating moderate reliability in examiner 2 (Table 5).

**Table 2.** Inter-examiner reliability in group I (8-16 years of age)

Radiographic Method	Examiner	ICC	95% Confidence interval (lower bound)	95% Confidence interval (upper bound)	P-value
Cross-sectional occlusal radiography	I	0.956	0.883	0.984	0.001*
	II				
CBCT	I	0.943	0.850	0.979	0.001*
	II				

\* Indicates a statistically significant difference (P<0.05) ; ICC: Intraclass correlation coefficient

**Table 3.** Inter-examiner reliability in group II (16-25 years of age)

Radiographic Method	Examiner	ICC	95% Confidence interval (lower bound)	95% Confidence interval (upper bound)	P-value
Cross-sectional occlusal radiography	I	1.000	1.000	1.000	1.000
	II				
CBCT	I	0.890	0.714	0.960	0.001*
	II				

\* Indicates a statistically significant difference (P<0.05) ; ICC: Intraclass correlation coefficient

**Table 4.** Reliability in group I (8-16 years of age)

Examiner	Radiographic Method	ICC	95% Confidence interval (lower bound)	95% Confidence interval (upper bound)	P-value
I	Cross-sectional occlusal radiography	0.579	0.152	0.824	0.006*
	CBCT				
II	Cross-sectional occlusal radiography	0.669	0.276	0.870	0.002*
	CBCT				

\* Indicates a statistically significant difference (P<0.05); ICC: Intraclass correlation coefficient

**Table 5.** Reliability in group II (16-25 years of age)

Examiner	Radiographic Method	ICC	95% Confidence interval (lower bound)	95% Confidence interval (upper bound)	P-value
I	Cross-sectional occlusal radiography	0.636	0.238	0.851	0.002*
	CBCT				
II	Cross-sectional occlusal radiography	0.573	0.125	0.827	0.008*
	CBCT				

\* Indicates a statistically significant difference (P<0.05) ; ICC: Intraclass correlation coefficient

Moreover, significant difference (P=0.097) was not observed in MPS ossification (anterior part: A-B) between cross-sectional occlusal radiographs and CBCT scans (Table 6).

According to the suture obliteration index, significant difference (p=0.031) did not exist in MPS ossification (anterior part: A-B) between cross-sectional occlusal radiographs and CBCT scans. Cross-sectional occlusal radiographs had a higher mean value (36.97) compared to CBCT (33.61), as presented in Table 7.

Significant difference (P=0.249) was not seen in MPS ossification (posterior part: B-P) between cross-sectional occlusal radiographs and CBCT scans.

According to the suture obliteration index, significant difference (P=0.035) did not exist in MPS ossification (posterior part: B-P) between cross-sectional occlusal radiographs and CBCT scans. Cross-sectional occlusal radiographs had a lower mean value (63.02) compared to CBCT (66.04) (Table 8).

A significant difference (P<0.001) was observed in MPS ossification (anterior part: A-B) between cross-sectional occlusal radiographs and CBCT scans. Cross-sectional occlusal radiographs had a lower mean value (13.75) compared to CBCT (24.86) (Table 9).

In the suture obliteration index, a significant difference (P<0.001) existed in MPS ossification (anterior part: A-b) between cross-sectional occlusal radiographs and CBCT scans. Cross-sectional occlusal radiographs had a lower mean value (33.83) compared to CBCT scans (66.23). According to the suture obliteration index, no significant difference (P=0.865) was seen in MPS ossification (posterior part: B-P) between cross-sectional occlusal radiographs and CBCT scans (Table 10).

No significant difference (P=0.244) was observed in MPS ossification (posterior part: B-P) between cross-sectional occlusal radiographs and CBCT scans (Table 11).

**Table 6.** MPS ossification (anterior part: A-B) in group I (8-16 years of age) (n=17)

Radiographic Method	Mean	Standard deviation	P-value
Cross-sectional occlusal radiography	13.71	1.45	0.097
CBCT	12.49	2.56	

**Table 7.** MPS ossification according to suture obliteration index in group I (8-16 years of age)

Anterior part A-B	N	Mean SOI	Standard deviation	p-value
Cross sectional occlusal radiography	17	36.97	3.00	0.031*
CBCT	17	33.61	5.36	
Posterior part B-P				
Cross-sectional occlusal radiography	17	63.02	3.00	0.035*
CBCT	17	66.04	4.77	

\* Indicates a statistically significant difference (P<0.05) ; SOI: Suture obliteration index

Radiographic Method	Mean	Standard deviation	P-value
Cross-sectional occlusal radiography	23.41	2.48	0.249
CBCT	24.65	3.57	

Radiographic Method	Mean	Standard deviation	P-value
Cross-sectional occlusal radiography	13.75	2.569	0.001*
CBCT	24.86	3.583	

\* Indicates a statistically significant difference (P<0.05)

Anterior part A-B	N	Mean SOI	Standard deviation	P-value
Cross-sectional occlusal radiography	16	33.83	4.848	0.001*
CBCT	16	66.23	4.866	
Posterior part B-P				
Cross-sectional occlusal radiography	16	66.16	4.846	0.865
CBCT	16	66.49	5.952	

\* Indicates a statistically significant difference (P<0.05); SOI: Suture obliteration index

Radiographic Method	Mean	Standard deviation	P-value
Cross-sectional occlusal radiography	26.88	2.335	0.244
CBCT	28.08	3.333	

## Discussion

Assessment of MPS ossification has a significant role in treatment planning for transverse discrepancy. Maxillary occlusal radiographs are widely used for assessment of MPS ossification because of less radiation exposure, economic advantage and ease of use. Since the first CBCT was approved by the FDA for dental use in the United States, CBCT has gained broad acceptance in dentistry during the past two decades.

Persson and Thilander (11) found that broad variations existed in different parts of the suture in the same individuals and in the degree of closure between subjects of the same group. Therefore, two groups were selected in the present study. Group I comprised patients aged 8 years to 16 years, and group II comprised patients 16 years to 25 years. Since the determination of MPS ossification is critical for the diagnosis, treatment planning, and outcome of RME, patients with transverse maxillary deficiency were selected for this study.

Angelier et al. (12) assessed CBCT images of 140 patients between 5.6–58.4 years, and it was observed that the majority of the adults had an

ossified MPS in the palatine and/or maxillary bone. However, in about 12% of the patients, the MPS was not fused. Sex and chronological age were not meaningful predictors of the maturational stage of MPS. Similarly, in the current study, assessment of the morphology of the suture revealed wide variations in patients over 20 years of age. In addition, such results are concordant with those of Revelo and Fishman's study (13), wherein a meaningful relationship existed between the conclusion of growth and commencement of ossification of the MPS and the presence of wide inter-individual variations in its ossification process.

Melsen and Melsen (9) evaluated palatal growth and mid-palatal suture morphology in humans between 0 to 18 years of age. They divided the morphological development of MPS into three stages. In the first stage, the suture was short, broad, and Y-shaped; in the second stage, it was more sinuous, and in the third stage, heavy inter-digitation was observed. In the present study, evaluation of the morphology of the suture was found to be similar to the findings of Melsen and Melsen (9).

In cross-sectional occlusal radiographs and CBCT scans, the inter-examiner reliability using ICC

was found to be 0.956 and 0.943 in the age group of 8 to 16 years, and 1.0 and 0.890 in the age group of 16 to 25 years, respectively, which indicated excellent reliability between the examiners in both age groups. It showed a high degree of agreement between the two examiners irrespective of the imaging technique.

By comparing CBCT and cross-sectional occlusal radiographs, the examiner reliability between cross-sectional occlusal radiographs and CBCT scans was assessed using ICC and it was found to be 0.579 (0.152, 0.824) and 0.669 (0.276, 0.870) indicating moderate reliability in examiner 1 and examiner 2, respectively, in the age group of 8 to 16 years. The same was true regarding the age group of 16 to 25 years. For MPS ossification stage assessment, both occlusal radiographs and CBCT scans could provide predictable results. Considering CBCT as the gold standard, a cross-sectional occlusal radiograph could also be used as an alternative but the accuracy of CBCT would be slightly higher compared to occlusal radiography.

For the age group of 8 to 16 years, there was no significant difference between cross-sectional occlusal radiographs and CBCT scans in the MPS ossification in the anterior part (A-B) and the posterior part (B-P). However, according to the suture obliteration index, a significant difference was seen in MPS ossification (anterior part: A-B; posterior part: B-P) between cross-sectional occlusal radiographs and CBCT scans. The cross-sectional occlusal radiographs showed a higher mean value (36.97) compared to CBCT (33.61) in the anterior part, and the cross-sectional occlusal radiographs had a lower mean value (63.02) compared to CBCT (66.04) in the posterior part.

Classification of MPS maturation by Angelieri et al. (12) appears to be an effortless method and is potentially a dependable predictor for clinical decision making. Moreover, it does not vary between different CBCT scanners (15), which is a great advantage. However, this method inhibits immediate comparison of the histological and CBCT findings regarding the suture morphology, and additional studies are necessary to validate the proposed maturation stages as the gold standard.

Calculation of the suture obliteration index suggested by Revelo and Fishman (13) revealed a significant difference in false readings that could potentially cause the clinicians to select the wrong treatment plan. Haghanifar et al. (16) evaluated ossification and morphology of the suture using CBCT and concluded age alone cannot reliably determine the developmental stage of the suture. Hence, it is reasonable to suggest that CBCT is

essential for assessing ossification and morphology of the MPS in all patients.

## Conclusion

The results of the present study demonstrated a broad variation in the commencement time and degree of ossification and morphology of the MPS in the diverse age groups. For MPS ossification stage assessment, both occlusal radiographs and CBCT scans provided results that helped in selecting the appropriate treatment plan.

Considering CBCT as the gold standard, cross-sectional occlusal radiographs can serve as an alternative but the accuracy of CBCT would be superior to occlusal radiography. Taking into consideration the factors such as cost, radiation exposure, and ease of technique, occlusal radiography could be used as it appears to be reliable to some extent. However, concerning differentiating treatment plans such as RME or SARME, it might not be truly dependable as it sometimes leads to false results. Therefore, using 3D imaging like CBCT is recommended for assessing the degree of ossification and morphology of the MPS in all patients. Further studies with larger sample sizes are advised to encourage future studies and establish conclusive evidence.

## References

1. Graber LW, Vanarsdall RL, Vig K. Orthodontics, current principles and techniques biomechanical considerations with temporary anchorage devices. Philadelphia, PA: Mosby. 2012; 2012:381-420.
2. Latham RA. The development, structure and growth pattern of the human mid-palatal suture. *J Anat.* 1971;108(Pt 1):31-41. PMID: 5100975
3. Bright JA. The importance of craniofacial sutures in biomechanical finite element models of the domestic pig. *PLOS one.* 2012;7(2): e31769. PMID: 22363727 doi: 10.1371/journal.pone.0031769
4. Kuroi J, Berglund L. Longitudinal study and cost-benefit analysis of the effect of early treatment of posterior cross-bites in the primary dentition. *Eur J Orthod.* 1992;14(3):173-9. PMID: 22666850 doi: 10.1093/ejo/14.3.173
5. Gungor K, Taner L, Kaygisiz E. Prevalence of posterior crossbite for orthodontic treatment timing. *J Clin Pediatr Dent.* 2016;40(5):422-4. PMID: 27617385 doi: 10.17796/1053-4628-40.5.422
6. Angell DH. Treatment of irregularity of the permanent or adult teeth. *Dent Cosmos.* 1860; 1:540-4.
7. Kilicoglu H, Kaya H, Kirlangiçoğlu S. Evaluation of The Compatibility of Howes Orthodontic Cast Analysis with Turkish Population. *Egypt Orthod J.* 2005;27(6):77-85. doi: 10.21608/eos.2005.79220



8. Fricke-Zech S, Gruber Rm, Dullin C, Zapf A, Kramer Fj, Kubein-Meesenburg D, Hahn W. Measurement of The Midpalatal Suture Width. *Angle Orthod.* 2012;82(1):145-50. PMID: 28461882 doi: 10.2319/040311-238.1
9. Melsen B, Melsen F. The postnatal development of the palatomaxillary region studied on human autopsy material. *Am J Orthod.* 1982;82(4):329-42. doi: 10.1016/0002-9416(82)90467-5
10. Melsen B. Palatal growth studied on human autopsy material: a histologic microradiographic study. *Am J Orthod.* 1975;68(1):42-54. PMID: 1056143 doi: 10.1016/0002-9416(75)90158-x
11. Persson M, Thilander B. Palatal suture closure in man from 15 to 35 years of age. *Am J Orthod.* 1977;72(1):42-52. PMID: 267435 doi: 10.1016/0002-9416(77)90123-3
12. Angelieri F, Cevidanes LH, Franchi L, Gonçalves JR, Benavides E, McNamara Jr JA. Midpalatal suture maturation: classification method for individual assessment before rapid maxillary expansion. *Am J Orthod Dentofacial Orthop.* 2013;144(5):759-69. PMID: 24182592 doi: 10.1016/j.ajodo.2013.04.022
13. Revelo B, Fishman LS. Maturation evaluation of ossification of the midpalatal suture. *Am J Orthod Dentofacial Orthop.* 1994;105(3):288-92. doi: 10.1016/S0889-5406(94)70123-7
14. Angelieri F, Franchi L, Cevidanes LH, Bueno-Silva B, McNamara Jr JA. Prediction of rapid maxillary expansion by assessing the maturation of the midpalatal suture on cone beam CT. *Dental Press J Orthod.* 2016;21(6):115-125. PMID: 28125147 doi: 10.1590/2177-6709.21.6.115-125.sar
15. Koo TK, Li MY. A Guideline of Selecting and Reporting Intraclass Correlation Coefficients for Reliability Research. *J Chiropr Med.* 2016;15(2):155-63. PMID: 27330520 doi: 10.1016/j.jcm.2016.02.012
16. Haghanifar S, Mahmoudi S, Foroughi R, Mir AP, Mesgarani A, Bijani A. Assessment of midpalatal suture ossification using cone-beam computed tomography. *Electron Physician.* 2017;9(3):4035-41. PMID: 28461882 doi: 10.19082/4035