

Interocclusal appliance effect on clinical findings and disc location in internal derangement

Minoo Mahshid ^a Mohammad Mehdi Zamiri ^b Masoud Ejlali ^c Masoud Varshosaz ^d
Ghassem Ansari ^f

Abstract

Aim: Improvement of clinical signs like pain and mandibular movements' restriction with capturing the natural disc location are among the main purpose of occlusal appliance therapy for the patients affected by internal derangement. The aim of this investigation was to determine the disc location and clinical findings in internal derangement patients, treated by an interocclusal appliance.

Materials and Methods: A total of 15 patients affected by internal derangement were selected on the basis of defined including and excluding criteria for treatment using a maxillary stabilization appliance. Patients were under detailed assessment in three occasions of before treatment, two and six months after the treatment. This was to determine the disc location in magnetic resonance imaging view and the effect of appliance on clinical findings like joint pain and mandibular movements restrictions. Descriptive statistical analysis and Friedman nonparametric test were used to analyse the data (SPSS Ver. 12.0)

Results: Improvements in clinical findings were observed in all (100%) patients after 2 months from the beginning of treatment and continued to be at 60% rate at the end of treatment. This improvement was found to be statistically significant when compared to other treatment sequences ($P < 0.001$). Disc shape remained unchanged after treatment (23 in normal condition and 7 deformed). In open position, 11 joints were diagnosed as normal, 7 joints with disc dislocation and reduction, 12 joints without reduction before and after treatment while only one joint was added to normal group from the dislocated discs groups with reduction. Statistical analysis did not show any significant difference between disc location before and after treatment.

Conclusion: Stabilization appliance improves clinical findings without disc recapturing. Continuous use of the appliance until six months increase, the treatment success rate in comparison to 2 months use (IJO 2006;1:145-53).

Key Words: : Interocclusal appliance, Clinical findings, Disc location, Internal derangement, TMD, TMJ.
(Received Jan 2008; Revised and accepted sept. 2008)

Internal derangement is a type of TMJ disorder associated with a dysfunctional condyle – disk complex. ¹ It is commonly associated with anterior and medial displacement or dislocation of the disc. It may be associated with clinical sounds, catch

^aAssociate Prof., Research Center, Dept. of Fixed Prosthodontics, Dental School, Shaheed Beheshti University of Medical Sciences, Tehran-Iran.

^bAssistant Prof., Dept. of Fixed Prosthodontics, Dental School, Shiraz University of Medical Sciences, Shiraz, Iran.

^cClinical Professor, Member of Staff, Dept. of Removable Prosthodontics, Dental School, Shaheed Beheshti University of Medical Sciences, Tehran-Iran.

^dAssistant Prof., Dept. of Oral and Maxillofacial Radiology, Dental School, Shaheed Beheshti University of Medical Sciences, Tehran-Iran.

^fAssociate Prof., Dept. of Pedodontics, Dental School, Shaheed Beheshti University of Medical Sciences, Tehran-Iran.

Corresponding Author:

Dr. M. Mahshid, Dept. of Prosthodontics, Dental School, Shaheed Beheshti University of Medical Sciences, Tehran-Iran.
E-mail: mdmahshid@yahoo.com.

and / or lock during jaw movements, limitation of jaw movements and even occasionally with pain.² Dislocation is categorized as reversible with recapturing or reduction of the disc and irreversible without the two in internal derangement disorder.^{3,6} History with a precise clinical examination of patients remain as gold standards for differential diagnosis of patients with internal derangement yet.^{7,9} However, clinical examination of temporomandibular joint has been supplemented by magnetic resonance imaging in the past 2 decades.^{10,12} This diagnostic modality has the distinct advantage of depicting both soft and hard tissue, thus a clinical diagnosis of anterior disc dislocation can be confirmed easily.^{13,14} Reversible type of treatment strategies are performed due to the severity of signs and symptoms in patients requiring treatment and multifactorial etiology of the disorder. One of the most common approaches in this field is performed by the fabrication of an interocclusal acrylic appliance.^{15,18} Elimination or reduction of joint symptoms (pain, restriction of mandibular movements) and re-establishment of a normal condyle-disc relationship are considered as two important criterias for selection the type of interocclusal appliances. Centric or stabilizing appliances and anterior positioning types are the most commonly used appliances. Several studies have reported varying degrees of success when using these appliances. While some reports suggest that anterior positioning appliance could be more efficient in relieving the joint symptoms that resulting in normal condyle disc relationship.^{19,27} Stabilization appliances are recommended as the first treatment option in the internal derangement cases in the fear of any permanent alteration of condylar position causing forward joint position.^{28,29} It is also believed, however, that normal relationship of condyl disc is never attainable in dislocated joints.^{30,34} The aim of this investigation was to evaluate the effect of an interocclusal appliance on clinical findings and disc location in internal derangement.

MATERIALS AND METHODS

Patients with a diagnosis of internal derangement who were referring to Postgraduate

Prosthodontics Department, Shaheed Beheshti Dental School, Tehran – Iran were selected and assigned for this investigation. They were then further assessed by a set inclusion criteria. These criterias include patients with intracapsular pain depicted differential diagnosis of manipulation test of Okeson without pain rise in jaw protrusion against resistance with unilateral separator (3) in addition to a minimum 3 of the following 4 criteria:

1. History of joint sound or catching
2. A sudden restriction of jaw opening (less than 35 mm of maximum opening without assistance of dentist).
3. Restriction of eccentric movement to the contralateral side (normal range of 7 mm).
4. Deflection of jaw in protrusive movement.

Exclusion criteria were, in the other hand, masticatory muscle disorders alone, growth disorders, inflammatory disorders of TMJ, chronic mandibular hypomobility, structural incompatibility of the articular surfaces.

The project was formally approved by review board of the Shaheed Beheshti Dental Research Center's for all subjects. History taking and clinical examinations were performed by assessment of the joints and muscles, manual inspection of joint sounds and pain, restriction, deviation and deflection based on Okeson and Dwarkin.^{3,7} Data was recorded from every clinical evaluation made by the operator and 2 independent investigators who have been calibrated before for this purpose. In order to record the form and location of the disc, and condyle disc relationship, a series of preliminary sagittal magnetic resonance images were acquired in open and close mouth positions for each joint before splint insertion. Scans were performed in T1 weighted protocol in close and open mouth positions stabilized by a mechanical hand made mouth opener to reduce blurred images in MRI, (Gyrosan ACS-NT- Phillips, Netherlands).

Magnetic resonance imaging (sagittal oblique) parameters included:

TE 20 (ms), TR 480 (ms), Matrix field of view 140 (mm), slice thickness 3 (mm), acquisition time 7.3 (min).

MRI evaluation was performed and data were then recorded in the forms papers without any

information from clinical examination in double blind sequence.

Disc location in closed position was classified as normal, anterior or posterior which is based on the position of posterior band of disc to head of condyle. In this regard, when the thickest part of posterior band of the disc was located between 12 and 1 o'clock, this was recorded as normal position, otherwise, it was considered as anterior or posterior location. In open position in anterior or posterior dislocated disc in close mouth position, if condyles bypass the thickest part of the disc in maximum opening, disc dislocation was diagnosed with reduction while otherwise disc dislocation without reduction was verified for each joint (Figs 1-3). Disc shape was also evaluated in closed mouth position, and normal shape was described biconcave lens-like configuration.³⁵

Based on the above mentioned criteria, 15 patients (14 females and 1 male) were allocated for this study.

Stabilization appliance was fabricated with defined criteria for all patients³⁶ using a heat processed acrylic resin (Meliodent, Heraeus, Kulzer, UK) (Fig. 4). Patients were advised to use their appliances 24 hours a day with the exception of meal times.²⁸ First follow up visit was monitoring at 2 weeks for assessing the correct use of appliance. Patients were reviewed at 2 and 6 months subsequently. Individuals were requested to report any problem or complication encountered.

Improvements in subjective and objective criteria (pain, restriction) were recorded as the

In addition, an occlusal adjustment of appliance was also performed if necessary. Reduction of joint pain, chronic pain and improvement of restriction of mandibular movements were considered as success criteria at this sequence of treatment. Joint pain assessed by clinical palpation of lateral pole and posterior attachment (criteria between 0 and 3, 0 without pain, 1 mild, 2 moderate and 3 severe).

Improvement of the degree of chronic pain was evaluated through the classification criteria between 0 (best) and 4 (worst) defined earlier.⁷

Those patients who demonstrate worsening of their signs and symptoms after 2 month review deserved anterior positioning appliance and new magnetic resonance imaging, while the use of appliance was continued for those who felt improvements until the end of treatment program (6 months).

Recordings were repeated at 6 months recall (end of treatment) in order to enable a comparison of the two steps of assessment. Magnetic resonance imaging for all patients was also conducted at the end of treatment.

Criteria for treatment success at 6 months evaluations were observed in comparison to 2 months regimen program including complete elimination or reduction of pain and complete submission or improvement of restriction during opening and eccentric movement in 6 months sequence.

Descriptive statistical analysis and Friedman nonparametric test were used to analyze the data with the significance level of < 0.05 .

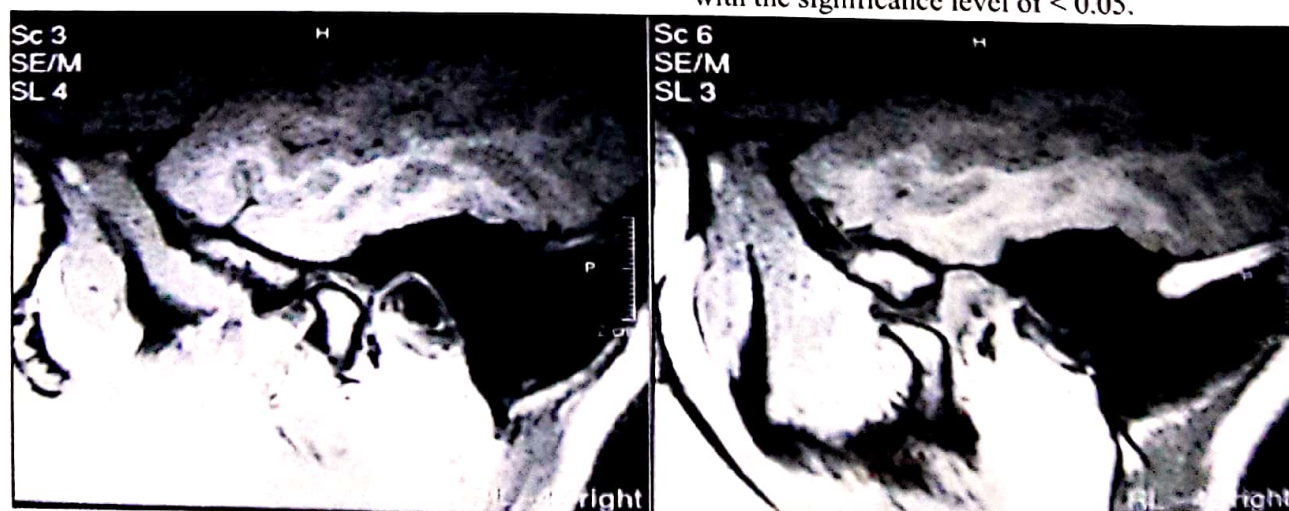


Fig. 1 – MRI sagittal view of condyle-disc complex in closed (left) and open position (Right) at normal status

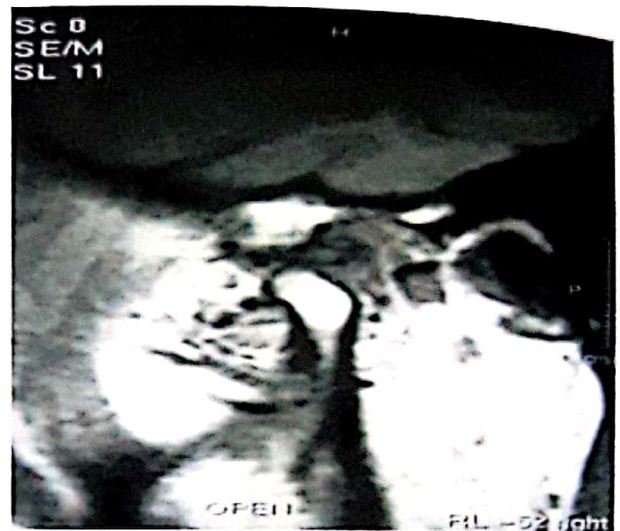
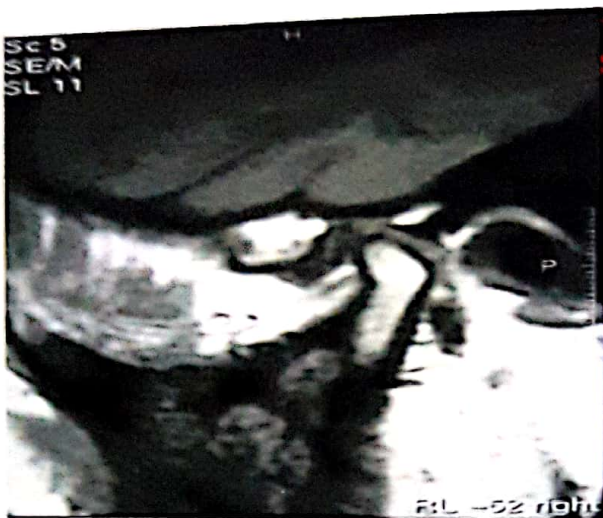

Fig. 2 - MRI sagittal view of condyle-disc complex in closed (left) and open position (Right) at reversible status

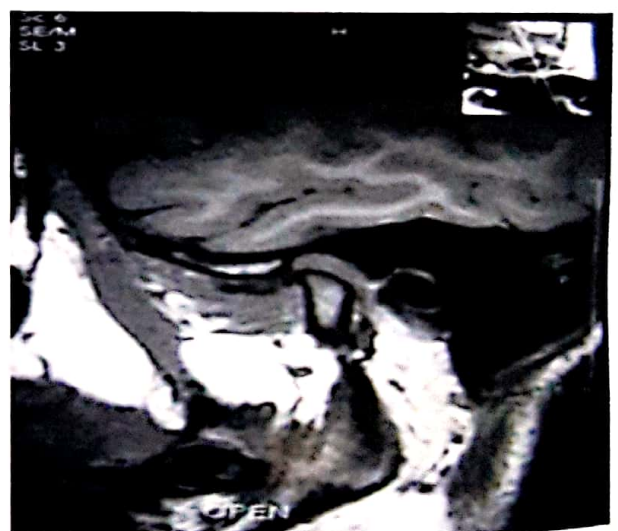
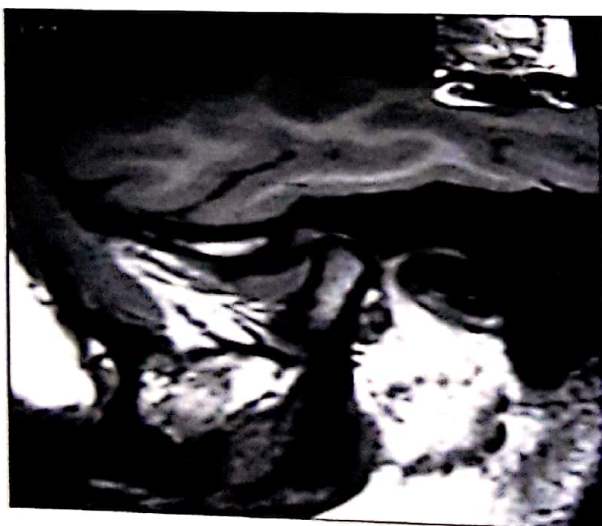
Fig. 3 - MRI sagittal view of condyle-disc complex in closed (left) and open position (Right) at irreversible status

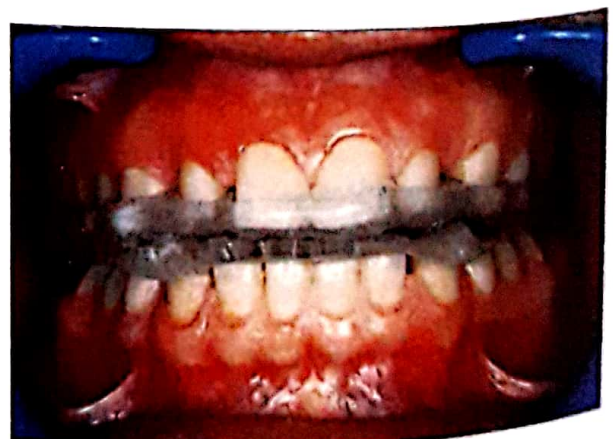
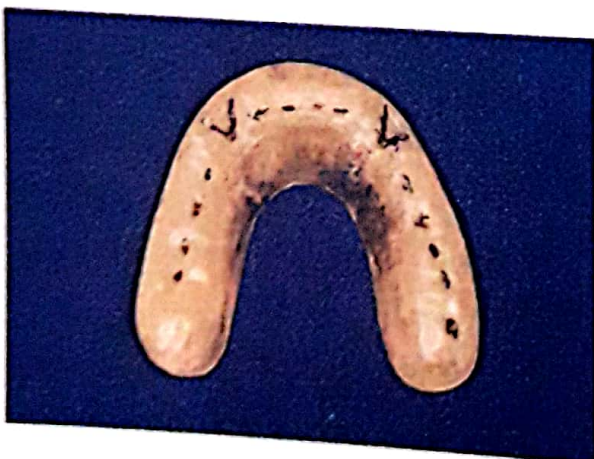
Fig. 4 - Stabilization appliance with even contacts

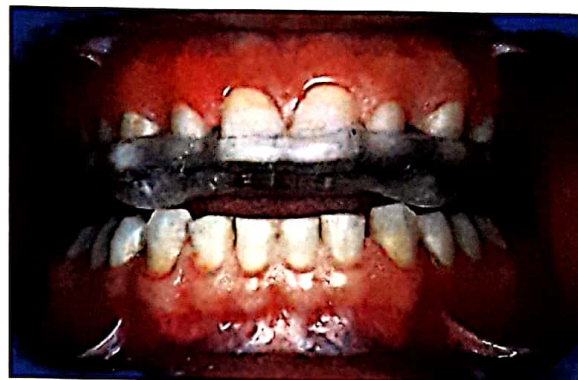
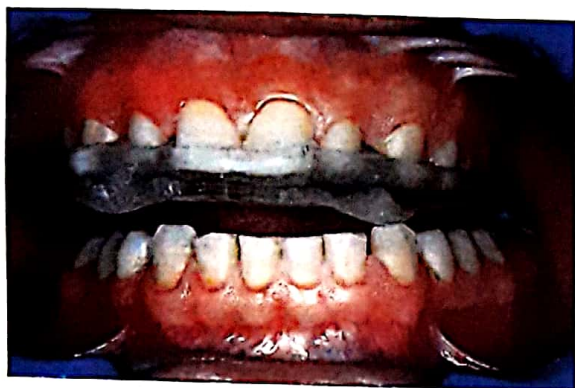
Fig. 5-Distribution of the degree of pain from palpation of right (R) and left (L) lateral pole at 3 time sequences assessed before and after treatment

RESULTS

From the total of 15 patients 14 were female with only 1 male. The average age of patients was 31.07 with a range of 18 to 53 years. Degree of chronic pain, showed dramatic decrease at 3 times sequences ($P < 0.001$). This value was 3 before treatment which reduced to 1.83 and 1.2 in 2 and 6 months respectively. Distribution of the degree of pain from palpation at right and left lateral pole showed also significant differences before and after treatment ($P < 0.001$), (Fig. 2,3). Distribution of the degree of pain from palpation at right and left posterior attachment region was found to be improved with a statistically significant difference when compared to other treatment sequences ($P < 0.001$), (Fig 4,5)

Significant differences were also found between the level of maximum mouth opening without assistance and eccentric mandibular movements in all 3 times observations of before treatment, 2 and 6 month after treatments ($P < 0.001$).

The disc location in sagittal view with closed mouth position did not show any significant difference ($P > 0.05$). The disc shape, however, remained unchanged after treatment (23 cases normal and 7 cases deformed). In open position, further assessments showed that 11 joints as being normal, 7 joints with disc dislocation and reduction. This was while 12 joints were without reduction. Only one single case was late shifted

to normal joint group from original joint with disc dislocation and reduction group. Statistical analysis didn't reveal any significant difference in disc location before and after the treatment, in these groups. Results of initial assessment also showed that 7 patients had deflection to the right and the same number to the left with 1 of the patients having deviation to the right during mouth opening prior to the treatment. This rate remained unchanged after 2 and 6 months follow up. Seven patients, however, still represented the right deflection, while 5 patients had left side deflection and 2 patients had right side deviation with only 1 patient having left side deviation.

DISCUSSION

Based on the results of the present study, a surprising 100% success rate was observed following 2 month appliance use with 60% success rate in comparison to the 2 month treatment outcome. Since a well defined inclusion criteria was used precisely in the current investigation, all selected patients were considered as having internal derangement. Differential diagnosis helps to fulfill this purpose in association to the MRI evaluation of reducible and non reducible disc which increases this precision. Improvement of clinical outcome (pain, range of mandibular movement) was

observed in patients using stabilization splints. Similar findings have been reported earlier with interocclusal appliances.^{15-17, 27, 28, 37-39}

To date, several different reasons are enumerated for the decrease in clinical complications following occlusal appliance therapy. These are including changes in neuromuscular behavior⁴⁰, decreased loading of temporomandibular joint⁴¹, cognitive awareness and placebo effect⁴² reduction of teeth effect on joint position⁴³, establishment of new equilibrium between muscles⁴⁴, increasing the vertical dimension of occlusion⁴⁵, formation of a retrodiscal fibrosis and establishment of a pseudodisc.^{46,47} Diversity in different factors of study set up and measurements, classification and evaluation criteria, makes comparisons of similar studies to each other slightly complicated.^{2,15,48,49}

There was no significant effect on joint sounds except in mouth opening, (left side) ($P < 0.05$) on 2 month treatment sequence. Sustained and retained joint sounds have already been reported similar to result of current study.^{2,15,39,46-51}

Relief of asymptomatic joint sounds should not be considered as a success criteria because presence of joint sounds after treatment (splint therapy) could effect on the treatment outcome by reducing evaluation scores.^{2,15}

Resistance of joint sounds would suggest that discal ligament do not tighten or shorten during the adaptation process of treatment.² The presence of joint sounds in epidemiologic studies have been reported to be relatively common. Many studies referred to the presence of joint sounds in a range of 28%-50% in adults.^{52,53} Progression of intracapsular disorders occur in 7-9% of patients as determined by joint sounds.⁵⁴⁻⁵⁶ Results also revealed that the disc form and location as being remained unchanged during and after the treatment, despite improvements in clinical finding. MRI findings demonstrated that disc capturing had occurred in only one out of 7 joints diagnosed with reversible disc dislocation. All of the other 12 joints were diagnosed as cases with irreversible dislocation and remained unchanged. Similar to some earlier reports,^{30,32-34} Kirk believed that the disc capturing is only a clinical term and in fact no actual change occurs in intra-articular anatomic relationships. This is due to an

inflammatory adhesion of displaced disc and its morphological changes.³¹

No deterioration was detected in signs and symptoms after 2 month recall. Therefore, none of the patients received any anterior positioning appliance. Earlier long term studies have also revealed that anterior positioning appliances are not as effective as once thought for joint dysfunction and recapturing the disc.^{31,57,58} and even their continuous use could cause consequences including dental instability.^{28,29} Shmitter reported stabilization splints to be more effective than distraction splints for improvement of pain and limitation of mandibular movements particularly prior to surgical treatment of anterior disc displacement without reduction.³⁸ As few other studies have also reported the disc dislocation is seen even in asymptomatic patients.⁵⁹⁻⁶² It should also needed to be considered that there are other responsible factors in producing pain and dysfunction independent of the disc dislocation.³²⁻⁶³ No correlation was observed between clinical remission of symptoms and positive radiographic findings of the current study. Even if the first purpose of appliance therapy is considered as the reduction of pain and dysfunction in internal derangement cases then current findings could support suggestions about the priority of stabilization appliances usage before invasive and irreversible therapy.^{15,28,29,38,64}

Since the return of symptoms must be evaluated in long – term bases, well defined clinical trials with standardized criteria are needed for patient selection and outcome evaluations which should be considered as the intention of the future research.

CONCLUSION

Stabilization appliances could decrease symptoms of internal derangement without disc recapturing. These appliances as a reversible and conservative type of treatment demonstrate significant effect on clinical problems. Continuous use of appliance for 6th months, improves symptoms in comparison to 2 months use.

Acknowledgement

This work has been sponsored by Shaheed Beheshti Dental Research Center and the authors would like to express their appreciations.

REFERENCES

- 1- Farrar WB. Characterization of the condylar path in internal derangements of the TMJ. *J Prosthet Dent* 1978;39:319-23.
- 2- Okeson JP. Long - term treatment of disk - interference disorders of TMJ with anterior positioning appliance. *J Prosthet Dent* 1988;60:611-616.
- 3-Okeson JP. Management of TMD and occlusion. 5th Ed. St Louis: The CV Mosby Co. 1998; Chap10:321-364.
- 4-Wilkes CH. Arthrography of the temporomandibular joint in patients with the TMJ pain, dysfunction syndrome. *Minn Med* 1978;61:645-625.
- 5-Katzberg RW. Temporomandibular joint imaging. *Radiology* 1989;170:297-307.
- 6-Orsini MG, Kubokit, Terada S, Matsuka Y, Yatani H, Yamashita A. Clinical predictability of tempromandibular joint disk displacement. *J Dent Res* 1999;78:620-66.
- 7-Dworkin SF, Lereche L. Research diagnostic criteria for temporomandibular disorders: Review, criteria, examination and specification, critique. *J Craniomand Disorders* 1992;6:301-357.
- 8-McNeill C. Science and practice of occlusion. 2nd Ed. Chicago: Quintessence publishing Co. 1997; Chap24:325-331.
- 9-Okeson JP: Long - term treatment of disk - interference disorders of TMJ with anterior positioning appliance. *J Prosthet Dent* 1988;Chap9:245-290.
- 10-Hansson IG, Westesson P-L, Katzberg RW, et al: MRI imaging of TMJ. comparison of images of autopsy specimens made at 0/3 and 1/5 with anatomic cryosections. *AJR Am J Roentgenol* 1989;152:1241-4.
- 11-Schwaighfer BW, Tanaka TT. MR imaging of TMJ: a cadaver study of the value of coronal images. *AJR Am J Roentgenol* 1990;154:1245-9.
- 12-Tasaki M, Westesson P-L. MR imaging of TMJ: diagnosis accuracy with sagittal and coronal imaging. *Radiol* 1993;186:723-729.
- 13-Liedberg J, Panmekiate A, Petersson A, et al. Evidence - based evaluation of three imaging methods for the temporomandibular disc. *Dentomaxillofac Radiol* 1996;25:234.
- 14-Katzberg RW, Westesson P-L. Magnetic Resonance imaging of TMJ. *Cranio Clin Int* 1991;1:93-97.
- 15-Tsuga K, Akagawa Y, Sakaguchi R, Tsuru H. A short term evaluation of the effectiveness of stabilization type occlusal splint therapy for specific symptoms of temporomandibular joint dysfunction syndrome. *J Prosthet Dent* 1989;61:610-13.
- 16-Goharian RK, Neff PA. Effect of occlusal retainers on temporomandibular joint and facial pain. *J Prosthet Dent* 1980;44:206-8.
- 17-Clark GT. A critical evaluation of orthopedic inter occlusal appliance therapy: Design, therapy and overall effectiveness. *J Am Dent Assoc* 1984;108:359-364.
- 18-Nassif NJ, Al - Chamdi KS. Managing bruxism and TMD using a centric relation occlusal device. *Compendium* 1999;20:1071-8.
- 19-Davies SJ, Gray RJM. The pattern of splint usage in the management of two common temporomandibular disorders. Part 1: The anterior repositioning splint in the treatment of disc displacement with reduction. *Br Dent J* 1997;183:199-203.
- 20-Gage JP. Diagnosis and treatment of TMJ dysfunction. Brisbane. The University of Queensland Dental School 1992;103-115.
- 21-Anderson GC, Schulte JK, Goodking RJ. Comparative study of two treatment methods for internal derangement of TMJ. *J Prosthet Dent* 1985;53:392-396.
- 22-Lundh H, Westesson PL, Kopps S, Tillstrom B: Anterior repositioning splint in the treatment of TMJs with reciprocal clicking. comparison with a flat occlusal splint and a untreated control group. *Oral Surg Oral Med Oral Pathol Oral Radiol Endod* 1985;60:131-136.

- 23-Lundh H, Westesson P-L, Jisander S, Erriksson L. Disk repositioning onlays in the treatment of TMJ disk displacement: comparison with a flat occlusal splint and with no treatment. *Oral Surg Oral Med Oral Pathol Oral Radiol Endod* 1988;66:155-162.
- 24-Santacatterina A, Paoli M, Perette R, Bambace A, Beltrame A. A comparison between horizontal splints in the treatment of DDWR. *J Oral Rehabil* 1998;25:81-88.
- 25-Kurita H, Ohtsuka A, Kurashina K, Kopp S. A study of factors for successful splint capture of anteriorly displaced TMJ disk with disc repositioning appliance. *J Oral Rehabil* 2001;28:651-657.
- 26-Kurita H, Kurashina K, Baba H, Ohtsuka A, Kopp S. Evaluation of disk capture with a splint repositioning appliance. Clinical and critical assessment with MRI imaging. *Oral Surg Oral Med Oral Pathol Oral Radiol Endod* 1998;85:377-380.
- 27-Simmons HC, Gibbs SJ. Recapturing of TMJ disk using anterior repositioning appliances: An MRI study. *J Of Craniomandibular Practice* 1995;13:227-237.
- 28-Carlsson GE, Magnusson T. Management of temporomandibular disorders in the general dental practice. 1st Ed. Quintessence Publishing Co. Inc. 1999;Chap11:101-109.
- 29-Okeson JP. Management of TMD and occlusion. 5th Ed. St. Louis: The CV Mosby Co. 1998;Chap13:437-490.
- 30-Manziane JV, Tallents R, Katzberg RW, Oster C, Miller T. Arthrographically guided splints therapy for recapturing the TMJ meniscus. *Oral Surg Oral Med Oral Pathol Oral Radiol Endod* 1984;57:235-24.
- 31-Kirk WS. MR imaging and tomographic evaluation of occlusal appliance treatment for advanced internal derangement of TMJ. *J Oral Maxillofac Surg* 1991;49:9-12.
- 32-Ornstein ES. Anterior repositioning appliance when used for anterior disk displacement with reduction: A critical review. *J Craniomandibular Pract* 1993;11:141-145.
- 33-Eberhard D, Bantelon H-P, Steger W. The efficacy of anterior repositioning splint therapy studied by magnetic resonance imaging. *European J Of Orthod* 2002;24:343-352.
- 34-Manco LG, Messing SG. Splint therapy evaluation with direct sagittal computed tomography. *Oral Surg Oral Pathol* 1986;61:5-11.
- 35-Okeson JP. Management of TMD and occlusion. 5th Ed. St. Louis: The CV Mosby Co. 1998;Chap15:468-498.
- 36-Shanon M, Palacios E, Valassori GE, Reed F: MRI of the normal TMJ. Clinical consideration, Radiography, management. 1st Ed. New York, Greece thieme Verlag Stuttgart 1990;Chap2:48-62.
- 37-Carrano JJ, Caffesse RG. Effect of occlusal splints on TMJ symptomatology. *J Prosthet Dent* 1978;40:563-6.
- 38-Schmitter M, Zahran M, Phu Duc J-M, Henschel V, Rammelsberg P. Conservative therapy in patients with anterior disc displacement without reduction using 2 common splints: A randomized clinical trial. *J Oral Maxillofac Surg* 2005;63:1295-1300.
- 39-Conti PCR, dos Santos CN, Kogawa EM, Conti AC de CF, Araujo C dRP. The treatment of painful temporomandibular joint clicking with oral splints. *JADA* 2006;137:1108-1114.
- 40-Schindler H, Rong, Spieß WEL. Der einfluss von aufbißschienen auf das rekrutierungsmuster des musculus temporalis. *Dtsch Zahnarztl Z* 2000;55:575.
- 41-Stegenga B, Dijkstra PU, deBond LG, Boening G. Temporomandibular joint osteoarthritis and internal derangement. Part II: Additional treatment options. *Int Dent J* 1990;40(6):341-53.
- 42-Kreiner M, Betancor E, Clark GT. Occlusal stabilization appliances. Evidence of their efficacy. *J Am Dent Assoc* 2001;132:770.
- 43-Grimm T, Gage JP. Preliminary studies on the use of MRI diagnosis of TMJ displacement. *Aust Prosthodont J* 1991;5:23.
- 44-Okeson J, Moody PM, Kemper JT, Haley JV. Evaluation of occlusal splint therapy and relaxation procedures in patients with temporomandibular disorders. *J Am Dent Assoc* 1983;107(3):420-4.
- 45-Shoji Y. Nonsurgical treatment of anterior disk displacement of the temporomandibular joint: A case report on the relationship between

condylar rotation and translation. *J Craniomandib Pract* 1995;13:270.

46-Isberg A, Isacson G, Johansson AS, Larson O. Hyperplastic soft – tissue formation in the temporomandibular joint associated with internal derangement: A radiographic and histologic study. *Oral Surg Oral Med Oral Pathol* 1986;61:32-38.

47-Pereira FJ Jr, Lundh H, Westesson PL. Microscopic changes in the retrodiscal tissues of painful temporomandibular joints. *J Oral Maxillofac Surg* 1996;54:461-468.

48-Kurita H, Kurashura K, Kotani A. Clinical effect of full coverage occlusal splint therapy for specific temporomandibular disorder conditions and symptoms. *J Prosthet Dent* 1991;78:506-10.

49-Linde C, Isacson G, Jonsson BG. Outcome of 6-week treatment with transcutaneous electronic nerve stimulation compared with splint on symptomatic temporomandibular joint disk displacement without reduction. *Acta Odontol Scand* 1995;53:92-98.

50-Boero RP. The physiology of splint therapy. *Angle Orthod* 1989;59:165-180.

51-Adler RC. A comparison of long – term post – management results of condylar – repositioned patients. *J Dent Res* 1986;11:473-479.

52-Hanson AT, Nilner M. A study of the occurrence of symptoms of disease of the TMJ, masticatory musculature and related structures. *J oral Rehabil* 1975;2:313-24.

53-Rieder CE, Martinoff JT, Wilcox SA. The prevalence of mandibular dysfunction. Part 1: Sex and age distribution of related signs and symptoms. *J Prosthet Dent* 1983;50:81-8.

54-Salonen L, Hellden L, Carlsson GE. Prevalence of signs and symptoms of dysfunction in the masticatory system: An epidemiologic study in an adult Swedish population. *J Craniomandible Disorder* 1990; 1:241-250.

55-Kononen M, Waltimo A, Nystrom M. Does clicking in adolescents lead to painful temporomandibular joint locking. *Lancet* 1996; 347: 1080-81.

56-Randolph CS, Green CS, Moretti R, Forbes D, Perry HT. Conservative management of temporomandibular disorders: a post treatment comparison between patients from a university clinic and from private practice. *Am J Orthod Dentofacial Orthop* 1990; 98: 77-89.

57-Choi BH, Yoo TH, Lee WY. Comparison of magnetic resonance imaging before and after nonsurgical treatment of closed lock. *Oral Surg Oral Med Oral Pathol* 1994; 78: 301-305.

58-Chen CW, Boulton JL, Gage JP. Effects of splint therapy in TMJ dysfunction: a study using magnetic resonance imaging. *Aust Dent J* 1995; 40:71-78.

59-Roberts C, Katzberg RW, Tallents RH, Espelan MA, Handelman SL. The clinical predictability of internal derangements of the temporomandibular joint. *Oral Surg Oral Med Oral Pathol* 1991; 71: 412-414.

60-Hatala M, Westesson P-L, Tallents RH, Katzberg RW. TMJ disk displacement in asymptomatic volunteers detected by MR imaging. *J Dent Res* 1991; 70: 278-282.

61-Westesson P-L, Eriksson L, Kuritta K. Reliability of a negative clinical TMJ examination: prevalence of oral displacement in asymptomatic TMJ. *Oral Surg Oral Med Oral Pathol* 1989; 68:551-554.

62-Rebeiro RF, Tallents RH, Katzberg RW, Murphy WC, Moss ME, Magalhees AC, Tavano O. The prevalence of disc displacement in a symptomatic and asymptomatic volunteers aged 6 to 25 years. *J Orofac Pain* 1997; 11: 37-47.

63-Barclay P, Hollender LG, Marvilla KR, Truelove EL. Comparison of clinical and MRI imaging, diagnosis in patients with disk displacement in TMJ. *Oral Surg Oral Med Oral Pathol Oral Radiol and Endodontics* 1999; 88: 37-43.

64-Ash MM. Current concepts in the etiology, diagnosis and treatment of TMJ and muscle dysfunction. *J Oral Rehabil* 1986;13:1-20