



# Comparison of the Gonial Angle in Panoramic and Lateral Cephalometric Radiographs in Different Skeletal Patterns

Foroozan Farahbod<sup>1</sup>, Sepideh Dadgar<sup>2,3</sup>, Farhad Sobouti<sup>3,4</sup>, Ali Malekzadeh Shafaroudi<sup>5</sup>, Sajad Yousefi<sup>1</sup>, Ali Norouzy<sup>5\*</sup>

<sup>1</sup>Assistant Professor of Oral and Maxillofacial Radiology, Department of Oral and Maxillofacial Radiology, Faculty of Dentistry, Mazandaran University of Medical Sciences, Sari, Iran

<sup>2</sup>Assistant Professor of Orthodontics, Department of Orthodontics, Faculty of Dentistry, Mazandaran University of Medical Sciences, Sari, Iran

<sup>3</sup>Dental Research Center, Faculty of Dentistry, Mazandaran University of Medical Sciences, Sari, Iran

<sup>4</sup>Associate Professor of Orthodontics, Department of Orthodontics, Faculty of Dentistry, Mazandaran University of Medical Sciences, Sari, Iran

<sup>5</sup>Student of Dentistry, Student Research Committee, Faculty of Dentistry, Mazandaran University of Medical Sciences, Sari, Iran

\*Corresponding author: Dentistry Student, Student Research Committee, Faculty of Dentistry, Mazandaran University of Medical Sciences, Sari, Iran. Email: ali.nowruzy7@gmail.com

Received: 2021 November 22; Revised: 2021 December 12; Accepted: 2021 December 20

## Abstract

**Background:** Superimposition of left and right structures is an issue in lateral cephalometric radiographs in dentistry, making it challenging to measure structures, including the gonial angle. Panoramic radiography contains fewer superimposing structures; therefore, it could measure the gonial angle. This study aimed to compare the gonial angle in panoramic and lateral cephalometric radiographs in different skeletal patterns.

**Methods:** In this cross-sectional study, 240 panoramic and lateral cephalometric radiographs were collected from the archives of Sari Dental School. The gonial angle of each radiograph was traced and measured with a conveyor. Data analysis was performed using ANOVA and paired t-test, and P-value <0.05 were considered significant.

**Results:** The paired t-test of the gonial angle did not show a statistically significant difference between different skeletal groups when measured using panoramic and lateral cephalometric radiographs. According to the results, the p-value of the difference between the right and left gonial angles in skeletal class III patients (p=0.019) was obtained larger than the test level (p=0.05). Therefore, it can be concluded that there is a statistically significant difference between the size of the left and right gonial angles in panoramic radiographs of skeletal class III patients.

**Conclusion:** Panoramic radiography can be an accurate alternative to lateral cephalometric radiographs for measuring the gonial angle in different skeletal patterns due to the lower radiation it exposes to the patient.

**Keywords:** Gonial angle, Panoramic radiography, lateral cephalogram, Orthodontics, Malocclusion

## 1. Background

One of the purposes of using radiography in orthodontics is to aid clinical diagnosis before treatment initiation. Radiographs may also be used to evaluate the effects of the treatment and determine the outcome and stability after the treatment (1). Panoramic radiography is intermittently used in orthodontic treatments to provide information about the axial inclination of the teeth, puberty, and the surrounding tissues of the teeth (2-4). Panoramic radiography provides an

accurate image of the left and right cranial structures with minimum radiation exposure to patients and technicians (5). Cephalometry is the gold standard for diagnostic goals at the beginning of orthodontic treatment. Many clinicians use this type of radiography for orthodontic treatments. In 2002, 90% of the orthodontists in the United States routinely used cephalograms (6). The gonial angle is studied in cephalometric analyses indicating the mandibular form. Evaluating the size of the gonial angle can help identify changes after orthodontic treatment. One of the applications of lateral

cephalometry in orthodontics is recording parameters such as gonial angle (7). In addition to cephalometry, panoramic radiography can also measure the gonial angle. Unlike lateral cephalograms, both right and left gonial angles can be easily measured in panoramic radiographs without the superimposition of anatomical landmarks (2). Some researchers have shown that the size of the gonial angle can be estimated using panoramic radiography with similar accuracy as lateral cephalometry (8), while others believe that there is a significant difference in the gonial angle measured in panoramic and cephalometric radiographs (9)

Due to the inconsistency in similar studies and the small and limited number of comprehensive studies comparing the gonial angle in all three different skeletal patterns in panoramic and lateral cephalometric radiography, this study aims to compare the gonial angle in lateral cephalometric and panoramic radiographs in different skeletal patterns.

## 2. Methods

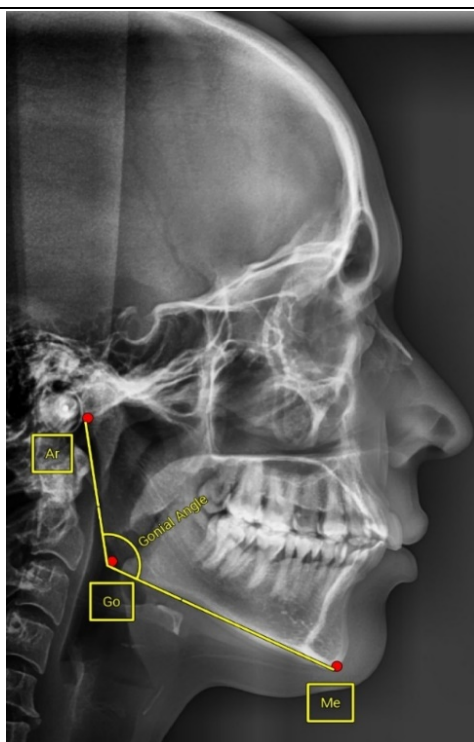
In this cross-sectional descriptive-analytical study, the study groups consisted of panoramic and cephalometric radiographs of orthodontic patients in the archive of the Department of Oral and Maxillofacial Radiology of Sari Dental School Clinic from 2014 to 2020.

In this study, 240 patients, including 120 females and 120 males in the age range of 9 to 35, were selected using a random sampling method. The samples consisted of 80 skeletal class I, 80 skeletal class II, and 80 skeletal class III specimens in terms of skeletal classification.

All radiographs with a high resolution in the archive were included in this study. Lateral cephalometric and panoramic images were taken using the same device (Planmeca ProMax 2D). In cephalometric radiographs, the natural head position was obtained so that the left and right mandibular borders were superimposed on each other; therefore, cephalograms with non-superimposed left and right borders were excluded from the study. The exclusion criteria of this study were history of past trauma, facial or mandibular surgery, syndromes and diseases affecting the jaw and face, and facial asymmetry.

In this study, Wits and Steiner analyses were used to distribute patients in different skeletal patterns. Panoramic images were taken by Planmeca ProMax 2D radiography equipment at 75 KVp, ten mA, and 17 s. In addition, Planmeca ProMax 2D took lateral cephalometric images at 75 KVp, 8 mA, and 0.061 s.

Down's mandibular plane measured the gonial angle in lateral Cephalograms. To do so, three points were joined, as presented in Figure 1 (9, 10).

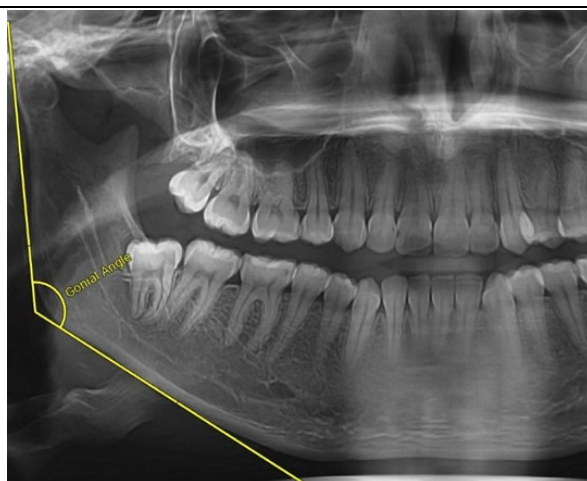


**Figure 1.** Measurement of the gonial angle in a Lateral Cephalometric radiograph

1. Ar: The intersection between the shadow of the zygomatic arch and the posterior border of the Ramos
2. Me: The lowest point on the mandibular symphysis
3. Go: The center of the lower contour of the mandibular angle

On each side of the panoramic view, the posterior plane of the ramus (the tangent line to the condyle border and the posterior border of the ramus) and the lower plane of the mandibular body (the tangent line to the lower

mandibular border) were drawn. The intersection of the two mentioned lines was considered the gonial angle (Figure 2). Cephalometric landmarks were identified and marked on the radiographs. First, the gonial angle in both radiographs was traced on tracing paper and then measured separately by an orthodontist and a general dentist (11). If the measurements were inconsistent, an oral and maxillofacial radiologist was responsible for correcting the measurements. The measurement accuracy was 0.5 degrees.



**Figure 2.** Measurement of the gonial angle in a Panoramic radiograph

After collecting the data, the minimum, maximum, mean, and standard deviation of the gonial angle were recorded separately in panoramic and lateral cephalometric radiographs for each skeletal group. The correlation between the gonial angle in panoramic and lateral Cephalometry radiographs was calculated and compared using the Pearson correlation coefficient in the different skeletal groups.

Analyses were performed using SPSS 22.0 (IBM SPSS Statistics for Windows, Version 22.0. Armonk, NY: IBM Corp. Released 2015.) ANOVA, t-test, and P-Value <0.05 were considered significant.

### 3. Results

In the present study, the gonial angles of 240 patients (120 females and 120 males), including 80 skeletal class I, 80 skeletal class II, and 80 skeletal class III, were measured in panoramic and lateral cephalometric radiographs.

Comparison of the left and right gonial angles in panoramic radiography with the gonial angle in lateral cephalometric radiography showed no statistically significant differences in none of the skeletal patterns (Table 1).

**Table 1.** Paired t-test for gonial angle in cephalometric and panoramic radiographs in patients with different skeletal patterns

Variable	Skeletal pattern	Pair differences		t	P-value	Pearson's correlation coefficient	P-value
		SD	Mean				
The left panoramic and cephalometric gonial angle	Class I	3.67	0.49	1.187	0.239	0.838	<0.001
	Class II	3.16	0.33	0.938	0.351	0.879	<0.001
	Class III	2.94	0.22	0.684	0.496	0.861	<0.001
The right panoramic and cephalometric gonial angle	Class I	3.78	0.04	0.089	0.930	0.821	<0.001
	Class II	3.03	-0.17	-0.497	0.620	0.894	<0.001
	Class III	3.36	0.47-	-1.248	0.216	0.825	<0.001

The present study compared the left and right gonial angles in panoramic radiographs in different skeletal patterns. The p-value in skeletal class I ( $p = 0.189$ ) and skeletal class II ( $p = 0.100$ ) were more significant than the test level ( $p = 0.05$ ) and, therefore, not considered statistically significant.

According to the results, the p-value of the difference between the right and left gonial angles in skeletal class III patients ( $p = 0.019$ ) was larger than the test level ( $p = 0.05$ ). Therefore, it can be concluded that there is a statistically significant difference between the size of the left and right gonial angles in panoramic radiographs of skeletal class III patients (Table 2).

**Table 2.** Paired t-test for right and left panoramic gonial angles in patients with different skeletal patterns

Skeletal pattern	Pair differences		t	P-value	Pearson's correlation coefficient	P-value
	Mean	SD				
Class I	3.04	-0.45	-1.324	0.189	0.888	<0.001
Class II	2.69	-0.50	-1.663	0.100	0.917	<0.001
Class III	2.58	-0.69	-2.403	0.019	0.895	<0.001

The gonial angles in lateral cephalometric and panoramic radiographs were compared in different genders (Table 3). As presented in table 3, no statistically significant differences were observed between the size of the gonial angles in lateral cephalometric and panoramic

radiographs in both genders.

The mean gonial angle size in the right panoramic left panoramic and lateral cephalometric were 127.18, 127.65, and 127.49 in women, and 126.63, 127.25, and 126.72 in men, respectively (Table 4).

**Table 3.** Paired t-test for the gonial angle in panoramic and cephalometric radiographs based on gender

Variable	Gender	SD	Pair differences	t	P-value	Pearson's correlation coefficient	P-value
			Mean				
The left panoramic and cephalometric gonial angle	Female	3.08	0.17	0.592	0.555	0.876	<0.001
	Male	3.43	0.53	1.690	0.094	0.850	<0.001
	Female	3.22	-0.30	-1.035	0.303	0.869	<0.001
The right panoramic and cephalometric gonial angle	Male	3.58	-0.10	-0.293	0.770	0.837	<0.001

**Table 4.** Independent t-test for the size of the gonial angle in panoramic and cephalometric radiographs based on gender

Variable	Gender	Number	Mean	SD	t	P-value
Panoramic right gonial angle	Female	120	127.18	6.49	0.691	0.490
	Male	120	126.63	6.01		
Panoramic left gonial angle	Female	120	127.65	6.34	0.509	0.697
	Male	120	127.25	5.97		
Cephalometric	Female	120	127.49	5.91	0.961	0.338
	Male	120	126.72	6.44		

The results indicated that the average size of the female gonial angle in both radiographs is slightly larger than that of men.

#### 4. Discussion

Lateral cephalometric radiography provides valuable information on the skeletal and dental aspects. Still, the superimposition of the left and right structures remains an issue, making measurements difficult, which is not the case in Panoramic radiography (10). Several studies have concluded that panoramic radiography can be

used instead of lateral cephalometry for measuring the gonial angle (4, 10, 12).

One of the gonial angle applications in orthodontics is to evaluate the need for surgery in skeletal class III patients undergoing conservative treatment (13). Since the examination of this angle in patients undergoing treatment requires a new cephalometric radiograph every year, the use of panoramic radiography can reduce costs and prevent additional radiation exposure to the patient (3).

This study found a strong correlation between panoramic radiographs' left and right gonial

angles and lateral cephalograms in all three skeletal patterns, though there were no statistically significant differences in any of the skeletal groups. ( $P$ -value > 0.05) (Table 1).

In Oksayan et al.'s study, the gonial angle was compared in panoramic and lateral cephalometric radiographs in all three skeletal groups, which showed no significant difference in any skeletal classes (3).

According to Chalipa et al., no statistically significant difference was observed between gonial angle in panoramic radiography and lateral cephalometric radiography in patients with division II malocclusion, which is consistent with the present study's findings. The correlation coefficient between the gonial angle in lateral cephalometry and the right panoramic radiography was 0.831. The correlation coefficient

between the gonial angle in lateral cephalometry and the right panoramic radiography was also reported 0.784 (10). The present study's relevant correlation coefficients in skeletal class II patients between the right and left panoramic radiographs and lateral cephalometry were 0.894 and 0.879, respectively (Table 1). Consistent with the present study results, Zangouei et al. reported no significant difference in the size of the gonial angle when measuring from lateral cephalometric and panoramic radiographs. In the Zangouei study, the mean value of the gonial angle in lateral cephalometric radiographs, right and left panoramic radiographs, were  $127.5 \pm 6.67$ ,  $127.36 \pm 6.88$ , and  $126.77 \pm 6.10$  respectively (7). The mean values of this angle in the present study were  $127.10 \pm 6.18$ ,  $126.90 \pm 6.25$ ,  $127.45 \pm 6.15$ , respectively (Table 5).

**Table 5.** Mean and standard deviation of gonial angle size in panoramic and lateral cephalometric radiography

Variable	Number	Mean	SD
Panoramic left gonial angle	240	127.45	6.15
Panoramic right gonial angle	240	126.90	6.25
Cephalometric gonial angle	240	127.10	6.18

Due to the remarkable similarity of these measurements, there is a slight difference in these values, which may be due to the difference between the radiographic equipment and small amounts of measurement error.

According to Adil et al., the gonial angle measured on the left and right sides of the panoramic radiograph was significantly different from the gonial angle measured on lateral cephalometric radiography, contrary to the results of the present study (14).

Memon et al. reported that the gonial angle size obtained by panoramic radiography was significantly different from the values measured by cephalometry using Tweed, Steiner, and Down methods (9). These differences could be due to the distortion in panoramic images and technical errors while taking the radiographs, such as not observing the natural head position. Also, technician errors might impact the measurements.

The present study obtained the highest correlation coefficient between the right and left gonial angle in panoramic radiography in skeletal class II patients (0.917). The lowest correlation coefficient was obtained between the right gonial angle in panoramic radiography and the gonial angle in lateral cephalometry in class I skeletal patients (0.821) (Table 1 and 2).

Comparison of the correlation coefficients between the right panoramic gonial angle and the gonial angle in lateral cephalometry in

different skeletal patterns is as follows:  $r_1$  (class I) >  $r_3$  (class III) >  $r_2$  (class II) (Table 1).

This relationship was also observed concerning the left gonial angle in different skeletal patterns. Therefore, it can be concluded that in all skeletal classes, there is a significant direct relationship between the size of the gonial angle in panoramic radiography and lateral cephalometry. Still, its rate is the highest in skeletal class II, moderate in class III, and the lowest in skeletal class I.

Comparing the size of the left and right gonial angles in panoramic radiography in class I and II skeletal patterns did not show a statistically significant difference (Table 2).

According to Chalipa et al., no significant difference was found between the left and right gonial angles in patients with division II malocclusion (10).

Comparing the left and right gonial angles in skeletal class III patients showed a statistical difference between the left and right gonial angles ( $P = 0.019$ ) (Table 2). The findings of this study regarding class III patients were similar to those of Raustia et al. (15). In the study of Oksayan et al., no significant difference was observed between the left and right gonial angles in any of the skeletal groups (3).

According to the present study results and previous studies, further studies are needed to compare panoramic radiographs' left and right gonial angles in different skeletal patterns.

However, in this study, the correlation between the right gonial angle in panoramic and lateral cephalometric radiography is slightly higher in women than men. Furthermore, the exact relationship is established between the left panoramic gonial angle and the gonial angle in lateral cephalometry.

Yet, no statistically significant difference was observed between the size of the gonial angle in lateral cephalometric and panoramic radiographs in both genders (Table 3).

Consequently, panoramic radiographs are reliable for measuring gonial angles in both genders. In the study of Shahabi et al., it is concluded for both genders and is consistent with the present study results (4).

Regarding the effect of gender on the gonial angle size, in the present study, the mean gonial angle size in women was slightly higher than in men. Still, no significant difference was observed between men and women. As a result, according to this study, gender does not significantly affect the size of the gonial angle (Table 5). Raustia et al. and Zangouei et al. also stated that gender has a non-significant effect on the size of the gonial angle, which is consistent with the present study results (15) (7).

Contrary to the results of these studies, Gungor et al. reported a significant difference between the size of the left gonial angle in men and women (16).

### Limitations and suggestions

The limited sample size was among the limitations of the present study. No intra-examiner tests were done to evaluate the measurement consistency in the present study, which is the other limitation of the present study. We recommend further studies conducted on other populations in different regions with larger sample sizes to obtain more accurate results.

### Conclusion

Panoramic radiography can be an accurate alternative to lateral cephalometric radiographs for measuring the gonial angle in different skeletal patterns due to the lower radiation exposure of patients.

### List of abbreviations

Not applicable

This article does not contain any studies with human or animal subjects performed by any authors.

### References

1. American Academy of Oral and Maxillofacial Radiology. Clinical recommendations regarding use of cone beam computed tomography in orthodontics. [corrected]. Position statement by the American Academy of Oral and Maxillofacial Radiology. *Oral Surg Oral Med Oral Pathol Oral Radiol.* 2013 Aug;116(2):238-57. doi: 10.1016/j.oooo.2013.06.002. Erratum in: *Oral Surg Oral Med Oral Pathol Oral Radiol.* 2013 Nov;116(5):661. PMID: 23849378.
2. Nejad A, Jamilian A, Meibodi S, Hafezi L, Khosravi S, Cappabianca S. Reliability of panoramic radiographs for determination of gonial and Frankfurt mandibular horizontal angles in different skeletal patterns. *Stoma Edu J.* 2016; 3:18-22.
3. Okşayan R, Aktan AM, Sökücü O, Haştar E, Ciftci ME. Does the panoramic radiography have the power to identify the gonial angle in orthodontics? *ScientificWorldJournal.* 2012; 2012:219708. doi: 10.1100/2012/219708. Epub 2012 Dec 13. PMID: 23365514; PMCID: PMC3532868.
4. Shahabi M, Ramazanzadeh BA, Mokhber N. Comparison between the external gonial angle in panoramic radiographs and lateral cephalograms of adult patients with Class I malocclusion. *J Oral Sci.* 2009 Sep;51(3):425-9. doi:10.2334/josnusd.51.425. PMID: 19776510.
5. Singh J, Kenneth T. To investigate the reliability of panoramic radiograph compared to that of a lateral cephalogram for assessing dentoskeletal pattern. *Indian J Dent Sci.* 2010; 2:49-60.
6. Nijkamp PG, Habets LL, Aartman IH, Zentner A. The influence of cephalometrics on orthodontic treatment planning. *Eur J Orthod.* 2008 Dec;30(6):630-5. doi: 10.1093/ejo/cjn059. Epub 2008 Nov 3. PMID: 18981169.
7. Zangouei-Booshehri M, Aghili HA, Abasi M, EzoddiniArdakani F. Agreement between panoramic and lateral cephalometric radiographs for measuring the gonial angle. *Iran J Radiol.* 2012 Nov;9(4):178-82. doi: 10.5812/iranjradiol.8444. Epub 2012 Nov 20. PMID: 23407613; PMCID: PMC3569548.
8. Katti G, Katti C, Karuna, Shahbaz S, Khan M, Ghali SR. Reliability of panoramic radiography in assessing gonial angle compared to lateral cephalogram in adult patients with Class I malocclusion. *J Indian Acad Oral Med Radiol* 2016; 28:252-5
9. Ul Haq MH, Memon S, Agha D. Comparison between three methods of gonial angle formation on lateral cephalogram and orthopantomogram. *J Pak Dent Assoc* 2018;27(2):57-61.
10. Chalipa J, Rezayani V, Khorshidian A, Hosseini MH, Ahmad Akhoundi MS. Comparison of panoramic radiography and lateral cephalometry in measurement of gonial angle in patients with Class II malocclusion. *J Isfahan Dent Sch.* 2009; 5(2): 75-80
11. Radhakrishnan PD, Sapna Varma NK, Ajith VV. Dilemma of gonial angle measurement: Panoramic radiograph or lateral cephalogram. *Imaging Sci Dent.* 2017 Jun;47(2):93-97. doi: 10.5624/isd.2017.47.2.93. Epub 2017 Jun 22. PMID: 28680845; PMCID: PMC5489674.
12. Bhullar MK, Uppal AS, Kochhar GK, Chachra S, Kochhar AS. Comparison of gonial angle determination from cephalograms and

- orthopantomogram. *Indian J Dent.* 2014 Jul;5(3):123-6. doi: 10.4103/0975-962X.140820. PMID: 25565740; PMCID: PMC4213870.
13. Tahmina K, Tanaka E, Tanne K. Craniofacial morphology in orthodontically treated patients of class III malocclusion with stable and unstable treatment outcomes. *Am J Orthod Dentofacial Orthop.* 2000 Jun;117(6):681-90. PMID: 10842111. Adil, S., Awan, M.H., Khan, I., & Syed, K. (2016). Comparison of the gonial angle measurements on Lateral Cephalogram and both hemispheres of Orthopantomogram. *Pakistan Orthodontic Journal*, 7, 48-50.
14. Adil S, Awan MH, Khan I, Syed K. Comparison of the gonial angle measurements on lateral cephalogram and both hemispheres of orthopantomogram. *Pak Orthod J.* 2016;7(2):48-50.
15. Raustia AM, Salonen MA. Gonial angles and condylar and ramus height of the mandible in complete denture wearers—a panoramic radiograph study. *J Oral Rehabil.* 1997 Jul;24(7):512-6. doi: 10.1046/j.1365-2842.1997.00532.x. PMID: 9250838.
16. Gungor K, Sagir M, Ozer I. Evaluation of the gonial angle in the Anatolian populations: from past to present. *Coll Antropol.* 2007 Jun;31(2):375-8. PMID: 17847912.