Comparison of mandibular tooth size magnification in digital panoramic view versus panoramic view reconstructed from Cone-Beam CT

Amirfarhang Miresmaeili[a], Shahriar Shahab[b], Faezeh Yousefi[c], Vahid Mollabashi[d]

Abstract

Aim: Tooth size in panoramic view has both magnification and distortion. It is supposed that panoramic view generated from Cone Beam computed tomography (CBCT) has more accurate tooth size compared with conventional panoramic view. The purpose of this study was to compare magnification of mandibular tooth size in digital panoramic radiographs andCBCT reconstructed panoramic images.

Materials and Methods: Amongpatients referred to Hamadan dental school, having both digital panoramic radiograph and CBCT, 28 patients were selected. Maximum width and length of mandibular teeth No. 36,34,33,31,41,43,44, 46 were measured in digital panoramic views and in CBCT reconstructed panoramic views. The CBCT images in multiple planes were used to give the dimensions referred to as gold standard. MANOVA test, Post Hoc and Tukey were used for statistical analysis.

Results: There was a significant difference in width and length of teeth between digital panoramic view and both reconstructed panoramic view and gold standard (P value< 0.05). In digital panoramic view the maximum and minimum of magnification was observed in incisors and molar teeth respectively. There were no statistical differences in width and length measurements between reconstructed panoramic view and gold standard except for magnification in incisor teeth width (P value> 0.05).

Conclusion: CBCT reconstructed panoramic views show significantly less magnification regarding tooth size compared with digital panoramic views.

Keywords: Panoramic Radiography, Cone-beam Computed Tomography, Radiographic magnification

(Received April2012; Revised and accepted July 2012)

Panoramic imaging is an important diagnostic adjunct in the assessment of skeletal and dental relationships in different field of studies[1].

[a]Associate professor, Orthodontics department, faculty of dentistry, Hamadan University of medical science

[b]Assistant professor of Oral and Maxillofacial Radiology department, Faculty of Dentistry, Shahed University

[c]Postgraduate student of oral and maxillofacial radiology department, faculty of dentistry, Hamadan University of medical science

[d] Assistant Professor, Orthodontics Department, School of Dentistry, Hamadan University of Medical Science

Corresponding author:
DrVahidMollabashi
Vahid.mollabashi@gmail.com

The principal advantages of this radiographic technique are the broad anatomic region imaged, the relatively low patient radiation dose, the convenience, ease, and speed of the procedure.[2]

Panoramic radiography has several shortcomings. [3,4] Concerning radiographic projection errors, magnification and distortion of skeletal and dental structures play important roles in final image.[5] Head positioning, anatomy of the patient jaw, tooth location within the dental arch and rotational parameters of the machine can all produce effects that do not accurately represent the patient.[6-9]Schiff etal. reported

that the most frequent errors in panoramic radiography occurred in patient positioning.[10]Although convenient to make, the panoramic radiograph is extremely technique and operator sensitive.[11]

Craniofacial Cone Beam Computed Tomography(CBCT) developed in late 1990s.These scanners offer 3D images from systems that are sufficiently compact and inexpensive.[12]CBCT data can be used to reconstruct traditional projection (2D) radiographic views, thus obviating the need for several exposures for multiple 2D images.[13]The images are already corrected for magnification, and as a result, accurate measurements can be derived from the reconstructed images.[7,14-16]

The measurement accuracy of CBCT images has been reported on several studies. Absence of magnification in CBCT had previously been proved by some authors. [17-19]In some studies there were no statistically significant differences between CBCT images and anatomic truth[20],whereas others illustrated differences that, even though statistically different, were not considered clinically significant.[17,21]Baumgaerteletal. found that the CBCT values tended to slightly underestimate the real values. This seemed to make no difference for single measurements but became significant for compound measurements (maxillary and mandibular arch length required and available), when several measurements were summed.[12]

Although precise tooth measurement is important in many fields of study like orthodontics and implantology, few studies have been done on differences of tooth width and length between panoramic radiography and CBCT.

The primary outcome parameter of this study was to compare magnification difference between two image modalities; Digital panoramic radiography and CBCT reconstructed panoramic view. CBCT images in multiple planes were used to give the dimensions referred to as gold standard.

Materials and Methods

Amongpatients referred to Hamadan dental school, having both digital panoramic radiograph and CBCT, 28 patients were selected. Digital panoramic radiographic machine was Cranex Tome Ceph (Soredex,Tuusula, Finland) and CBCT scanner was Newtom3G (Quantitative Radiology, Verona, Italy). In this cross sectional study mandibular first molar, first premolar, canine and central incisors of both sides were selected. In digital panoramic radiographs, width and length of selected teeth were measured using digora for Windows (DfW)software (Figure1).

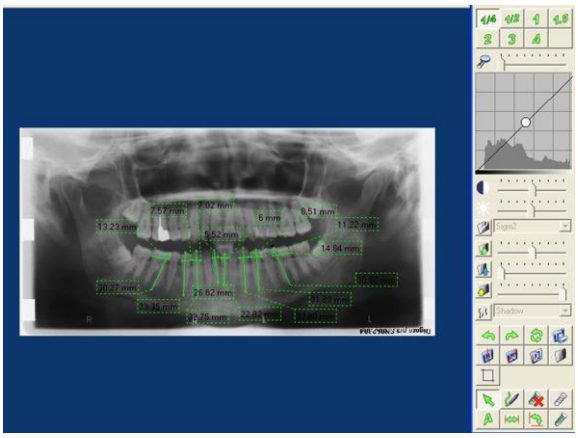

Figure1. Tooth size measurements in digital panoramic view

In the second image modality, measurements were done using NNT software after reconstruction of panoramic view from originalCBCT (Figure2). The line indicating the panoramic reconstruction was drawn from the mandibular occlusal plane in the axial view.The Slice thickness for reconstructingpanoramicswas 25 mm.

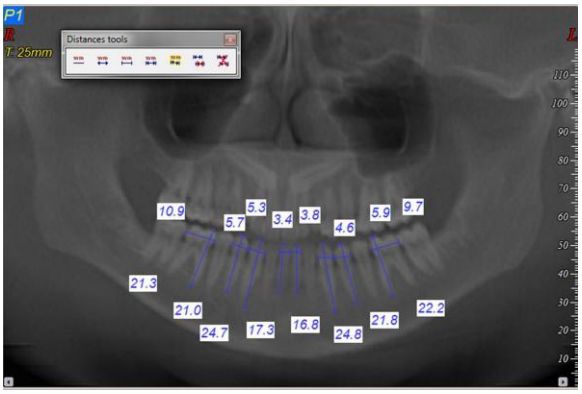

Figure2. Tooth size measurements in CBCT reconstructed panoramic view

Original CBCT was used as a gold standard to measure width of teeth in multi planar views (mainly on axial view) while maximum length of selected teeth was measured on 3D tools.

Manova test was used for statistical analysis and post hoc was used to detect any differences between the two imaging modalities.

Right and left molars(54 teeth) in three image modalities were measured twice with 10 day interval and analyzed with intra class correlation coefficient to determine Intraoperator reliability

Results

Width and length of totally 212 teeth of 28 patients (15 female, 13 male)with mean age of 23.8±10.8 years, were evaluated in three image modalities. Means and standard deviations of tooth measurements are shown in Table 1.

Manova test showed significant differences between groups ($p < 0.05$). Post hoc test showed that, therewas a significant magnification in width and length in digital panoramic radiography relative to other two groups. CBCT reconstructed panoramic and gold standard showed no significant difference except in incisor width.

Magnification ratio of conventional panoramic images relative to reconstructed images was variable in different tooth areas. There was 1.16 to 1.46magnification in width and 1.24 to 1.31 magnification in length.

Intraoperatorreliabilitywasin acceptable range(Table 2).

Discussion

Prescription of both CBCT and conventional images is not usually allowed because of ethical problems; in this study we decided to use available radiographic images retrospectively and we didn't accessto otherpatients'records like dental casts, so we used the CBCT as the best available standard. This comparison has been confirmed according to the previous studies which showed nosignificant difference between CBCT and real measurements.[12,17-19]

The result of thepresent studyshowed a significant tooth size magnificationin digital panoramic image relative to CBCT reconstructed panoramic.Magnification in panoramic view may be due to several factors such as head positioning,rotational parameters of the machine and predefined image creation lines which produce variable magnification in different tooth location within the dental arch. In CBCT images,head positioning errors were minimized because orientation adjustment is possible after exposure. On the other hand since the reconstructed images from original CBCT are orthogonal,rotational parameter problems are not applicable in CBCT scans. Individualized image creation line in each patient according to axial view makes magnification in different tooth locations at its minimum level.

Our CBCT imageshowed no magnification regardless of the tooth location. Yimetal. evaluated the tooth image measurements

Table 1. Means and standard deviations of tooth measurements in three image modalities

Measurement(mm)	Digital panoramic		CBCT reconstructed		Gold standard	
	Mean	SD	Mean	SD	Mean	SD
Right molar width	12.78	1.56	10.98	0.91	10.6	1.21
Right premolar width	7.81	0.95	6.44	0.56	6.65	0.63
Right canine width	7.77	1.29	5.72	0.76	6.61	0.62
Right incisor width	5.35	0.78	3.71	0.61	4.63	0.46
Left molar width	12.91	1.33	10.64	0.69	10.7	0.55
Left premolar width	7.91	0.91	6.14	0.56	6.68	0.6
Left canine width	7.79	1.22	5.66	0.69	6.47	0.58
Left incisor width	5.49	0.98	3.76	0.71	4.65	0.43
Right molar length	26.08	3.95	20.08	2.19	18.51	2.07
Right premolar length	25.15	3.3	20.2	2.01	19.57	2.37
Right canine length	29.03	3.84	22.93	2.5	22.66	2.7
Right incisor length	21.58	3.56	17.39	1.91	18.46	2.6
Left molar length	27.3	4.07	20.7	2.48	18.72	2.66
Left premolar length	25.76	3.06	20.25	2.05	19.71	2.22
Left canine length	28.58	3.82	22.63	2.66	22.85	3.09
Left incisor length	21.8	3.42	17.36	2.05	18.47	2.56

Table 2. Intraoperator reliability for three image modalities measurements

Measurement(mm)	Digital panoramic	CBCT reconstructed	Gold standard
Right molar width	0.962	0.759	0.638
Left molar width	0.935	0.832	0.834
Right molar length	0.85	0.641	0.932
Left molar length	0.77	0.843	0.979

according to the tooth location and calculated the magnification rate in digitalized panoramic andCBCT images.19Hefound a vertical magnification of about 1.28 to 1.09 in panoramic images relative to CBCT, depending on the tooth location.In our study magnificationin length wasbetween 1.31in canine region and 1.24 in anterior region. We have not found any magnification report in horizontal dimension in previous studies. But this study showed 1.16 to 1.46 magnification in width that increased from the anterior site to the posterior. Different magnification ratio in different dimensions and different locations in panoramic radiography makes it inappropriate to apply a general magnification ratio covering the whole image. Instead we must consider different magnificationratios for better image interpretation

Thesignificant decreaseof tooth sizein CBCT reconstructed panoramic relative tomulti planar CBCT only in incisor width needs special consideration. This underestimation could be the result of some errorswhen thecentral line for image creationis marked over occlusal plane in axial view to produce an image in which both the crown and the apex of incisor teethbe visible.In this way the width of image layer must be wider than usual and the image sharpness decreases due to this thickness increase.There may also be some systematic errors in the CBCT software that produces inaccurate mimic of mandibular curve and therefore induce some errors.[12,17] In addition some inherent image features including different slice thicknesses and voxel size for the reconstructed panoramic images and the different CBCT machines may have effect.

Conclusion

CBCT reconstructed panoramic views show significantly less magnification regarding tooth size compared with digital panoramic views. In this image only the width of incisor teeth showeddifferent size relative to gold standard.

References

1- Moshiri M, Scarfe WC, Hilgers ML, Scheetz JP, Silveira AM, Farman AG. Accuracy of linear measurements from imaging plate and lateral cephalometric images derived from cone-beam computed tomography. Am J Orthod Dentofacial Orthop 2007;132:550-60.

2- McKee IW, Williamson PC, Lam EW, Heo G, Glover KE, Major PW. The accuracy of 4 panoramic units in the projection of mesiodistal tooth angulations. Am J Orthod Dentofacial Orthop 2002;121:166-75.

3- Quintero JC, Trosien A, Hatcher D, Kapila S. Craniofacial imaging in orthodontics: historical perspective, current status, and future developments. Angle Orthod 1999;69:491-506.

4- Garcia-Figueroa MA, Raboud DW, Lam EW, Heo G, Major PW. Effect of buccolingual root angulation on the mesiodistal angulation shown on panoramic radiographs. Am J Orthod Dentofacial Orthop 2008;134:93-9.

5- Manuel O. Lagravère aJC, b Roger W. Toogood,c and Paul W. Majord. Three-dimensional accuracy of measuremensmade with software on cone-beam computed tomography images. (Am J Orthod Dentofacial Orthop 2008;134:112-6.

6- Harrell WE, Jr., Hatcher DC, Bolt RL. In search of anatomic truth: 3-dimensional digital modeling and the future of orthodontics. Am J Orthod Dentofacial Orthop 2002;122:325-30.
7- Haney E, Gansky SA, Lee JS, Johnson E, Maki K, Miller AJ et al. Comparative analysis of traditional radiographs and cone-beam computed tomography volumetric images in the diagnosis and treatment planning of maxillary impacted canines. Am J Orthod Dentofacial Orthop 2010;137:590-7.
8- Batenburg RH, Stellingsma K, Raghoebar GM, Vissink A. Bone height measurements on panoramic radiographs: the effect of shape and position of edentulous mandibles. Oral Surg Oral Med Oral Pathol Oral Radiol Endod 1997;84:430-5.
9- Ha CH CK, Kim JS. Comparison of the image magnification in the jaws according to the types of panoramic machines. J Kor Oral Maxillofac Radiol 1991;21:287-296.
10- Schiff T, D'Ambrosio J, Glass BJ, Langlais RP, McDavid WD. Common positioning and technical errors in panoramic radiography. J Am Dent Assoc 1986;113:422-6.
11- McKee IW, Glover KE, Williamson PC, Lam EW, Heo G, Major PW. The effect of vertical and horizontal head positioning in panoramic radiography on mesiodistal tooth angulations. Angle Orthod 2001;71:442-51.
12- Baumgaertel S, Palomo JM, Palomo L, Hans MG. Reliability and accuracy of cone-beam computed tomography dental measurements. Am J Orthod Dentofacial Orthop 2009;136:19-25; discussion 25-18.
13-John F. Sherrard aPER, b Byron W. Benson,c Roberto Carrillo,d and Peter H. Buschange. Accuracy and reliability of tooth and root lengths measured on cone-beam computed tomographs. Am J Orthod Dentofacial Orthop 2010;137:100-8.
14- Ludlow JB, Gubler M, Cevidanes L, Mol A. Precision of cephalometric landmark identification: cone-beam computed tomography vs conventional cephalometric views. Am J Orthod Dentofacial Orthop 2009;136:312 e311-310; discussion 312-313.
15- Lamichane M, Anderson NK, Rigali PH, Seldin EB, Will LA. Accuracy of reconstructed images from cone-beam computed tomography scans. Am J Orthod Dentofacial Orthop 2009;136:156 e151-156; discussion 156-7.
16- Gribel BF, Gribel MN, Frazao DC, McNamara JA, Jr., Manzi FR. Accuracy and reliability of craniometric measurements on lateral cephalometry and 3D measurements on CBCT scans. Angle Orthod 2011;81:26-35.
17- Ballrick JW, Palomo JM, Ruch E, Amberman BD, Hans MG. Image distortion and spatial resolution of a commercially available cone-beam computed tomography machine. Am J Orthod Dentofacial Orthop 2008;134:573-82.
18- Mah J, Hatcher D. Three-dimensional craniofacial imaging. Am J Orthod Dentofacial Orthop 2004;126:308-9.
19- Yim JH, Ryu DM, Lee BS, Kwon YD. Analysis of digitalized panorama and cone beam computed tomographic image distortion for the diagnosis of dental implant surgery. J Craniofac Surg 2011;22:669-73.
20- Hilgers ML, Scarfe WC, Scheetz JP, Farman AG. Accuracy of linear temporomandibular joint measurements with cone beam computed tomography and digital cephalometric radiography. Am J Orthod Dentofacial Orthop 2005;128:803-11.
21- Lascala CA, Panella J, Marques MM. Analysis of the accuracy of linear measurements obtained by cone beam computed tomography (CBCT-NewTom). Dentomaxillofac Radiol 2004;33:291-4.