ORIGINAL ARTICLE

A comparison of third molar angulation changes after Extraction and Non-Extraction orthodontic treatment

M.Kachoei
Associate Professor, Orthodontic Department, Faculty of Dentistry, Tabriz University of Medical Sciences, Tabriz, Iran
M.H.AhangarAtashi
Associate Professor, Orthodontic Department, Faculty of Dentistry, Tabriz University of Medical Sciences, Tabriz, Iran
A.Mohammadi
Assistant Professor, Orthodontic Department, Faculty of Dentistry,Tabriz University of Medical Sciences, Tabriz, Iran
S. BadamchiZadeh
Postgraduate Student, Prosthodontic Department, Faculty of Dentistry, Hamadan University of Medical Sciences, Hamadan, Iran
M. Khobivand
Postgraduate Student, Radiology Department, Faculty of Dentistry, Isfahan University of Medical Sciences, Isfahan, Iran

Introduction: Third molar impaction is usually related to lack of space for eruption. The aim of this study was to assess third molar angulation following extraction and non extraction orthodontic treatment.

Methods: This study was carried out on pretreatment and post treatment panoramic and cephalometricradiographs of 70 CL I malocclusion patients. Thirty-five patients (24 female and 11 male) with mean age of 16.3±1.8 years had been treated with extraction of four first premolars (extraction group) and thirty-five patients (27 female and 8 male) with mean age of 16.9±2.6 years had been treated without extraction (nonextraction group). In each group, upper and lower third molar angulation, on pre and post treatment radiographs were assessed. Changes in third molar angulations from pretreatment to post treatment in each group were assessed with Mann- Whiteny U test . Changes in two groups were compared with Wilcoxon test.

Results: statistical analysis revealed some degree of improvement in third molar angulation in both groups .changes of upper left third molars in extraction group and upper right and lower left third molars in non extraction group were statistically significant .

The changes of third molar angulation between two groups were not statistically significant.

Conclusion: Extraction of first premolars during orthodontic treatments does not influence unerupted third molar angulation.

Key words: Angulation, Extraction, Non-Extraction, third molar.

Received 10February 2014; accepted 4March 2014;Published 7 June 2014
Corresponding Author: Mahdieh- Nourzadeh
Assistant Professor, Endodontic Department, Faculty of Dentistry, Zanjan University of Medical Sciences, Zanjan, Iran
Sources of support:Tabriz University of Medical Sciences.
Address: Endodontic Department, Faculty of Dentistry, Safa St. ,Zanjan, Iran
Tel: 0098 241 4255550
E-mail: m_nourzadeh1986@yahoo.com

Introduction

The third molars begin to develop at the age of 7-15 and are the last teeth that develop in the dental arches (1).Their development is influenced by many variables like genetics or even nutritional regimens in different societies (2).

The average age of third molar eruption ranges from 17-21, but roots are not fully formed until 18-25.Various studies have demonstrated that these teeth have the highest incidence of impaction than any other teeth (3,4,5). Inadequacy of retromolar space may play a role in the impaction of third molar. If the remodeling of the ascendingramus is arrested , the eruption of third molar will come to standstill, Similarly reduced posterior growth of the tuberosity can hinder the eruption of upper third molar (4,5).

Impacted third molars are a major problem in modern dentistry and the decision of whether to remove an impacted third molar is probably one of the most frequent challenges in the decision making process for dentists. some of the impacted teeth are asymptomatic, but they can also cause complications such as pain, infection, cysts, tumor, jaw fractures, caries and root resorption of the adjacent teeth or malposition of the mandibular anterior teeth (6).

Eruption of third molar and their effect on the dental arches have been a site of debate for a long time. Many studies have been conducted to find out the effect of third molar eruption on mandibular incisors crowding .The results imply the increased prevalence of lower incisor crowding in patients with erupted third molars (7).

Factors that contribute in impaction of third molars and it's prediction have been studied extensively but there are few studies that investigate the effects of orthodontic treatment on eruption of third molars(8).

Space deficiency is one of the reasons of third molar impaction .with this in mind, is it possible to utilize remnant space of extracted premolars in order to pave the way for eruption of third molar.

Saysel (3) and Artun (9) investigated the effect of first premolar extraction on angulation of third molars; they found that extraction of first premolars significantly improve the angulation of third molars. Ay et al also reported that patients who underwent first permanent molar extraction, had a better position of third molars as a result of increased retromolar space (4). On the other hand there are some other studies which show that extraction of premolars do not have any significant effect on angulation or eruption of third molars(8,10,11). The aim of this study was to determine the changes in the angulation of upper and lower third molars in class I cases following extraction and non extraction orthodontic treatments.

Material & Methods

This retrospective study was carried out at department of orthodontics of dental faculty, Tabriz university of medical sciences .Records belonging to 70 patients with age range of 15-25 years were studied. 35 patients(24 female and 11 male) with mean age of 16.3±1.8 years ,who had undergone orthodontic treatment with all first premolar extraction was considered as extraction group. Nonextraction group comprised of 35 ones(27 female and 8 male) with mean age of 16.9±2.6 years,who had been treated without extraction. pre-treatment and post-treatment lateral cephalogram and panoramic radiographs were evaluated.

Inclusion criteria was:

1-presence of pre-treatment and post-treatment lateral cephalogram and panoramic radiographs in patients document.

2-Skeletal and dental Cl I relationship

3-Complete eruption of all teeth but third molars before treatment

4- Unerupted third molars which were visible in pre-treatment panoramic radiographs.

5-No missing, no previous extraction

6- crowding less than 5mm in non extraction group and more than 9mm in extraction group

All the radiographs were undertaken in a single center using the same machine (planmeca,Helsinki,Finland)

Exclusion criteria:

1- The need for extraction of any other teeth rather first premolars
2- Necessity of extraction of third molar during treatment

3- Inability to draw the long axis or occlusal plane of third molar in cephalogram or panoramic radiograph due to its severe malformation
4- Non extraction treatment with distal molar movement mechanics.

In the extraction group, first premolars had been extracted and space closure had been done with moderate anchorage preparation using 0.018 or 0.022 inch straight wire system.The arch had been expanded transversely and anteroposteriorly in non-extraction group .It is note worthy that the posterior segment in these patients hadn't been distalized.

Pre-treatment and post-treatment lateral cephalogram and panoramic radiograph were traced.

Lateral cephalogram analysis:

The occlusal plane proposed by Down, was used in lateral cephalometric tracings. Left upper and lower third molars which are more clear in latralcephalogram were traced, The angle between the occlusal surface of upper third molar and palatal plane (U8/PP) and the angle between occlusal surface of upper third molar and occlusal plane(U8/OP) were measured as angulations of upper third molars before and after the treatment. Scale of superioposterior angle was recorded before and after treatment. Decrease in these angles (negative values) were deemed as improvement of angulation.

The angle between occlusal surface of lower third molar and mandibular plane (L8/MP) and the angle between the occlusal surface of lower third molar and occlusal plane (L8 /OP) were measured before and after treatment. Decreasing in these angles(negative values) were reffered as improvement of angulation. Mesial and distal angulations were received positive and negative values respectively (9)(Fig. 1).

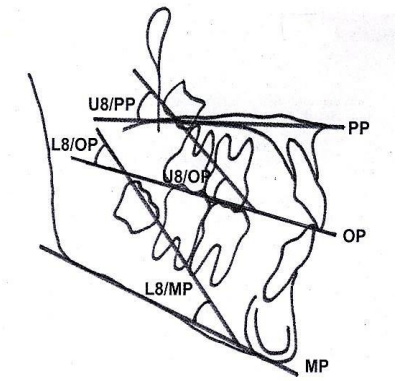

Fig 1. the angles of upper third molar (U8/OP), (U8/PP) and lower third molar (l8/PP), (l8/OP) in lateral cephalogram

Panoramic radiograph analysis:

In panoramic radiographs, occlusal plane was drawn through the cusp tip of first molars to those of second premolars .Long axis of third molar was drawn through the center of its crown, perpendicular to occlusal surface. The long axis drawn before and after treatment had to be coincident (3) supero anterior angle between upper molar long axis and occlusal plane and infero anterior angle between lower molar long axis and occlusal plane before and after treatment ,and difference between them(right and left side separately) were recorded. Increase in angle related to U8 (positive values) and decreasing in angle related to L8 (negative values) were reffered as improvement of angulation (Fig. 2).

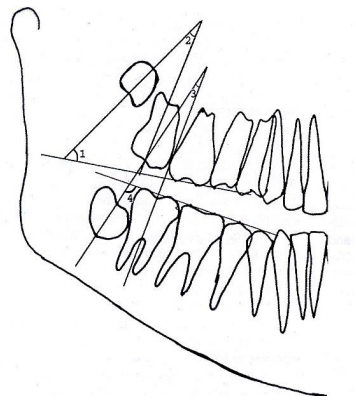

Fig 2. the angle between the occlusal plane and long axis of upper and lower third molars in panoramic radiographs

All of the tracings were drawn on the acetate paper by one orthodontist. The reproducibility of the measurements was assessed by statistically analyzing the difference between double measurements taken two week apart on 10 randomly selected radiographs. The error was calculated from the equation(9, 10, 12):

$$S = \sqrt{\frac{\Sigma D^2}{2N}}$$

D is the difference between duplicated mesurments, N is the number of double measurements and S is the error variance.

The Data were analyzed using SPSS 14/win software and descriptive analysis (mean+ SD) was calculated for each group before and after treatment. Kolmogorov-

Smirnov test was used to confirm normal data distribution .The distribution was not tenable so non-parametric analyses were used .Comparison of pretreatment angles in extraction and non-extraction groups were done with Mann- Whiteny U test .Comparison of before and after treatment values within each group was done with Wilcoxon signed rank test. Mann- Whiteny U test also was used to compare the mean of angular changes between the two groups.

Results

The results obtained from Wilcoxon signed rank test in comparing the pre-and post treatment showed that in extraction group all angulations had some sign of improvement but only improvement of upper left third molars angulation in panoramic radiographs (pl-U8/OP)was statistically significant(p=0.01). There was no significant difference between other values before and after treatment (table 1).

Table 1. Analysis of correlation between vertical dental variants and smile qualitative variants in both sexes*.
R= correlation coefficient
P= 2- tailed significance
Significant correlations (P< 0.005) are shown by bold characters.
*Spearman's rho

angle	number	pretreatment	posttreatment	Difference between pretreatment andposttreatment values	* P
c_U8/OP	35	17.93	13.829	-4.1000	0.149
c_U8/PP	35	31.79	27.457	-4.3286	0.130
c_L8/OP	35	30.743	30.59	-0.1581	0.858
c_L8/MP	35	14.99	12.714	-2.2714	0.195
rp_U8/OP	35	78.20	80.029	1.8286	0.304
lp_ U8/OP	35	71.73	76.086	4.3571	*0.010
rp _L8/OP	35	125.929	122.76	-3.1714	0.085
lp _L8/OP	35	125.20	119.011	-6.1886	0.110

Results of Wilcoxon Signed Ranks analysis in comparing the pre-and post treatment values in Non-Ext group showed that all angulations had some sign of improvement .There was no significant improvement but cl-L8/OP angle(p=0.004) and rp-U8/OP angle(table 2).

Table 2. Results of Wilcoxon Signed Ranks analysis comparing angular changes in Non- Ext group before and after treatment
c: cephalometric radiograph, p: panoramic radiograph, r: right, l: left
P*, P Value<0.05 is statistically significant

angle	number	pretreatment	posttreatment	Difference between pretreatment andposttreatment values	* P
c_U8/OP	35	22.50	20.614	-1.8857	0.550
c_U8/PP	35	35.56	30.143	-5.4143	0.559
c_L8/OP	35	31.27	25.329	-5.9429	*0.004
c_L8/MP	35	16.46	13.929	-2.5486	0.090
rp _U8/OP	35	68.19	73.829	5.6429	*0.01
lp _ U8/OP	35	70.74	73.086	2.3429	0.537
rp _L8/OP	35	121.900	119.61	-2.2857	0.617
lp _L8/OP	35	118.17	114.971	-3.2000	0.939

Mann-Whitney U analysis comparing the angular changes during treatment did not show any significant difference between the two groups. Improvement in most of angles was slightly more in extraction than non extraction group, as seen in table 3.

Table 3. Results of Mann-Whitney U analysis comparing angular changes during treatment between two groups
c: cephalometric radiograph, p: panoramic radiograph, r: right, l: left
P*, P Value<0.05 is statistically significant

angle	number	Mean of angular changes in Ext group	Mean of angular changes in Non-Ext group	* P
c_U8/OP	35	-4.1000	-1.8857	0.585
c_U8/PP	35	-4.3286	-5.4143	0.888
c_L8/OP	35	-1.1571	-5.9429	0.167
c_L8/MP	35	-2.2714	-2.5286	0.681
rp _U8/OP	35	1.8286	5.6429	0.071
lp _ U8/OP	35	4.3571	2.3429	0.226
rp _L8/OP	35	-3.1714	-2.2857	0.388
lp _L8/OP	35	-6.1886	-3.2000	0.197

Discussion

in this study pre-treatment and post-treatment lateral cephalogram and panoramic radiographs in two groups were evaluated. The changes in the angulation of upper and lower third molars in class I cases following extraction and non extraction orthodontic treatments were compared .Our study showed that all angulations had some sign of improvement in both extraction and non extraction groups, but only improvement of upper left third molars angle (lp-U8/OP) in extraction group and improvement of upper right(rp-U8/OP)and lower left third (c-L8/OP)molars angles in non extraction group were statistically significant . Angular changes during treatment did not show any significant differences between the two groups. Findings of some previous studies are similar to our survey. Haavikko (13) and Staggers(8)examined the effect of extraction of first premolars on angular development of third molars and concluded that the angulation of third molar were improved in both extraction and non- extraction groups but it was not statistically significant.

Some studies came to conflicting results with the current study. Saysel (3) examined panoramic radiographs of patients with the mean age of 11-15 years and demonstrated that extraction of premolars significantly improve third molar angulation. Artun(9) examined the lateral cephalometric radiographs of patients with the mean age of 12.3years,and Jains (14) on panoramic radiographs of patients with mean age of 15 years found that extraction therapy is associated with a significant improvement in third molar angulation.

Age variation in these studies may be a factor that has influenced these results. We chose the age range of 15-25years in this study. Since uprighting occurs predominantly in early adolescence, the impact of orthodontic treatment is more obvious in these years and most of orthodontic patients that undergo fixed appliance therapy fall into this category.

Most of the studies have merely examined the panoramic radiographs

(3, 12,13,15), and one study has used lateral cephalometric radiograph (9). Measurement of angular changes on cephalogram by itself may introduce superimposition errors .This may be a site of difference by its own. So to solve this problem we used both panoramic and lateral cephalometric radiographs. Some studies concluded that extraction of premolars has no effect on the eruption of third molars (11,16,17). Present study like previous ones not predict the eruption of third molars following extraction of first premolars in definite manner.

We suggest further studies to determine the reasons of difference between position of the left and right sides and a comparison with those individuals who have not received any form of treatment.

Conclusion and clinical significance

Present study like previous ones not predict the eruption of third molars following extraction of first premolars in definite manner. So the clinicians should explain the patient that premolar extraction does not guarantee the eruption of third molars.

Acknowledgement

The authors would like to express their gratitude to Tabriz University of Medical Sciences for scientific and financial support of this study.

References:

1-Kandasamy S, Woods MG. Is orthodontic treatment without premolar extractions always non-extraction treatment?Aust Dent J. 2005; 50: 146-51.

2- Erdem D, Ozlider E, Memikoglu UT, Baspinar E. Third molar impaction in extraction cases treated with the Begg technique. Eur J Orthod.1998; 20: 263-70.

3- Saysel MY, MeralGD,Kocadereli I, TasarF.The Effects of First Premolar Extractions on Third Molar Angulations. Angle Orthod. 2005; 75: 719-22.

4- Ay S, Agar U,Bicakci AA, Kosger HH. Changes in mandibular third molar angle and position after unilateral mandibular first molar extraction.Am J OrthodDentofacialOrthop.2006; 129: 36-41.

5- Kim TW, Artun J, Behbehani F, Artese F. Prevalence of third molar impaction in orthodontic patients treated nonextraction and with extraction of 4 premolars.Am J OrthodDentofacial Orthop.2003; 123: 138-45.

6- Celikoglu M, Miloglu O, Kazanci F. Frequency of Agenesis, Impaction, Angulation, and Related Pathologic Changes of Third Molar Teeth in Orthodontic Patients. J Oral MaxillofacSurg; 68: 990-5.

7- Capelli J. Mandibular growth and third molar impaction in extraction cases.*AngleOrthod*. 1991; 61: 223-9.

8- Staggers JA, Germane N, Fortson WM.A comparison of the effects of first premolar extractions on third molar angulation. Angle Orthod. 1992; 62: 135-8.

9- ArtunJ, Thalib L, Little MR. Third Molar Angulation During and After treatment of adolescent orthodontic patients. Eur J Orthod.2005; 27: 590-96.

10- Graber TM, KainegTF.The mandibular third molar--its predictive status and role in lower incisor crowding.Proc Finn Dent Soc. 1981; 77: 37-44.

11-Gungormus M. Pathologic status and changes in mandibular third molar position during orthodontic treatment. J Contemp Dent Pract.2002; 3: 11-22.

12- Janson G, Putrick LM, Henriques JFC, Freitas MR, Henriques RP. Maxillary third molar position in class || malocclusions: the effect of treatment with and without maxillary premolar extractions. EurJOrthod. 2006; 28: 573-9.

13- Haavikko K, Altonen M, Matilla K. Predicting angulational development and eruption of the lower third molar. Angle Orthod. 1978; 48: 39-48.

14- Jain S, Valiathan A. Influence of First Premolar Extraction on Mandibular Third Molar Angulation.AngleOrthod. 2009; 79: 1143-8.

15- Orton-Gibbs S, Crow V, Orton HS.Eruption of third permanent molars after the extraction of second permanent molars. Part 1:Assessment of third molar position and size. Am J OrthodDentofacialOrthop. 2001; 119: 226-38.

16- McCoy JR. Astudy of growth potential from observations made in over 50 years of orthodontic practice. Am J Orthod.1965; 51: 79-97.

17- Forsberg CM. Tooth size, spacing, and crowding in relation to eruption or impaction of third molars. Am J OrthodDentofacialOrthop.1988; 94: 57-62.