Iran J Ortho. 2019 September; 14(2):e102222. doi: 10.5812/ijo.102222.

Published online 2020 May 3. **Research Article**

Cephalometric Evaluation of Maxillary and Mandibular Centers of Rotation Subsequent to Maxillary and Mandibular Surgery

Delaram Shahbodaghi [1], Tahereh Hosseinzadeh Nik [2, 3], Mohammad Sadegh Ahmad Akhundi [2, 3], Shahab Kavousinejad [2] and Atefe Saffar Shahroudi [2, 3, *]

[1] Faculty of Dentistry, Tehran University of Medical Sciences, Tehran, Iran
[2] Department of Orthodontics, Faculty of Dentistry, Tehran University of Medical Sciences, Tehran, Iran
[3] Dental Research Center, Dentistry Research Institute, Tehran University of Medical Sciences, Tehran, Iran

[*] *Corresponding author*: Faculty of Dentistry, Tehran University of Medical Sciences, North Kargar St., Tehran, Iran. Tel: +98-9124070738, Fax: +98-2142494000, Email: a-shahroudi@tums.ac.ir

Received 2020 February 26; **Revised** 2020 April 21; **Accepted** 2020 April 28.

Abstract

Background: Due to significant effect of joint orthodontic and surgical treatment planning on the patients' facial appearances, precise prediction of surgical outcomes is of great importance.
Objectives: The aim of this study was to determine the maxillary and mandibular centers of rotation and its distance to center of condyle (CC) in patients who underwent maxillary impaction surgery concomitant with mandibular advancement or setback surgery and also to determine the correlation between maxillary center of rotation (MxCR) with that of mandible (MnCR) and also the direction of rotation in distal and proximal segments of the mandible.
Methods: Preoperative and postoperative lateral cephalograms of 24 adult non-syndromic patients were studied. Using cephalometric tracings MxCR was located as the intersection of ANS-PNS (preoperative) and ANS'-PNS' (postoperative) lines. MnCR was located using Reuleaux method, where perpendicular bisectors of B-B' and Go-Go' lines meet. Using statistical analysis of correlation and comparison, all the points' coordinates and centers of rotation were compared.
Results: The average distance of MnCR to CC was 10.45 cm and the average distance of MxCR to CC was 8.39 cm. MxCR and MnCR had positive correlation in horizontal plane and they had negative correlation in vertical plane but the correlation was insignificant ($P > 0.05$). In addition, there seemed to be no specific pattern in the direction of mandibular proximal and distal segments' rotations.
Conclusions: The results showed that: (1) The center of rotation calculated for mandible after bimaxillary surgery was not located within the condylar area. But generally whenever MxCR was closer to ANS, MnCR was located more anteriorly. (2) In patients with decreased distance between MxCR and SN line, MnCR would be located more superiorly. Also, whenever MxCR had greater distance from condyle, the MnCR to condyle distance was greater too. (3) The direction of rotation in proximal and distal segments of mandible had no specific pattern.

Keywords: Maxillary Impaction Surgery, Mandibular Setback, Mandibular Advancement, Cephalometric Prediction, Center of Rotation

1. Background

In the treatment of the patients with orofacial deformity, a combination of orthodontic treatment and orthognathic surgery is needed. Therefore, a very precise treatment plan should be set before any clinical procedure. One of the most important stages of treatment planning for candidate of surgeries is prediction of treatment outcome by means of cephalometric analysis and dental casts. Cephalometric prediction lets the clinicians evaluate the changes in the position of teeth, jaws and soft tissue following the surgery (1). The precision of these predictions depends on the method used for predicting the movements as long as the precision of surgical procedure (2). Any failure in these processes would lead to undesirable esthetic and functional outcome and patient dissatisfaction. Therefore, many researchers have studied the best methods for cephalometric prediction of final position of hard and soft tissue (3).

One of the most common treatment for patients with excessive lower facial height and or anterior open bite is surgical impaction of maxilla. This procedure results in counterclockwise rotation of the mandible around a center of rotation, forward positioning of the chin, decrease in facial height, and increase in overbite (4-6) which makes

it crucial to do a precise prediction before planning the orthodontic and surgical treatment.

Many researches tried to find the exact location of the center of rotation of the mandible (MnCR) during its auto-rotation following maxillary impaction but it has been reported to exhibit significant variation (7-10).

Sperry et al. reported that the MnCR during its auto-rotation following maxillary impaction is in the mastoid region (7). In two other studies on patients who had maxillary impaction surgery, the center of rotation (CR) of mandible in its auto-rotation was found to be lower and posterior to condylar CR with a high inter-personal variety (10, 11). Another study found no significant difference between the three reference point of condylar hinge axis, condilyon and mastoid point (9). Nadjmi et al concluded that following maxillary impaction surgery, mandible rotates around same center as it does during the early stage of natural mouth opening movements (12). It was also reported that if the condylar radiographic center be considered as the CR of mandibular auto-rotation following a mean 5-mm maxillary impaction, horizontal position of the chin would be overestimated to 2 mm and its vertical position would be underestimated to 1.3 mm (10). Gimenez et al. evaluated the predictability of cephalometric analysis in bimaxillary surgical-orthodontic treatment outcomes in long face pattern patients. They compared the precision of hand and computerized tracing with the real outcomes and reported a higher precision for hand tracing relative to computerized one (13).

Although several studies had yet addressed the CR of mandible during its auto rotation following maxillary impaction in mono-max surgeries, not enough studies have been done on the CR of mandible in bi-max surgeries which include mandibular surgery.

2. Objectives

Accordingly, the aim of this study was to evaluate the center of rotation of mandible and maxilla in patients underwent maxillary impaction with mandibular advancement or setback.

3. Methods

Pre-surgical and post-surgical lateral cephalograms of 24 patients who had orthognathic surgery including maxillary impaction with mandibular advancement or setback was gathered from the archive of orthodontic department of Tehran University of Medical Sciences. The cephalograms were made all in the Radiology department of Dental School of Tehran University of Medical sciences with the same device. Patients with any oro-facial syndromes, facial asymmetry and maxillary cant as well as those patients whose cephalograms did not have good quality were excluded. All samples were adult patients between the age of 19 and 34 with the mean age of 22.6-year-old. Cephalograms were traced by hand method using black and red soft pencil and transparent tracing paper on a portable negatoscope. All landmarks and planes were checked by two experienced orthodontists. Cranial vault, cranial base, naso-maxillary complex, mandible, upper and lower incisors, upper and lower firs molar, occlusal plane and condyles were drawn and then cephalometric landmarks including, Sella (S), Nasion (N), center of condyle (C), A point, B point, Menton (M), Anterior nasal spine (ANS), Posterior Nasal Spine (PNS), and Gonion (Go) were defined. The plane of sella-nasion (SN) was considered as horizontal reference plane (X axis) and a line which was perpendicular to this plane at the point of S was considered as the vertical reference plane (Y axis) (Figure 1).

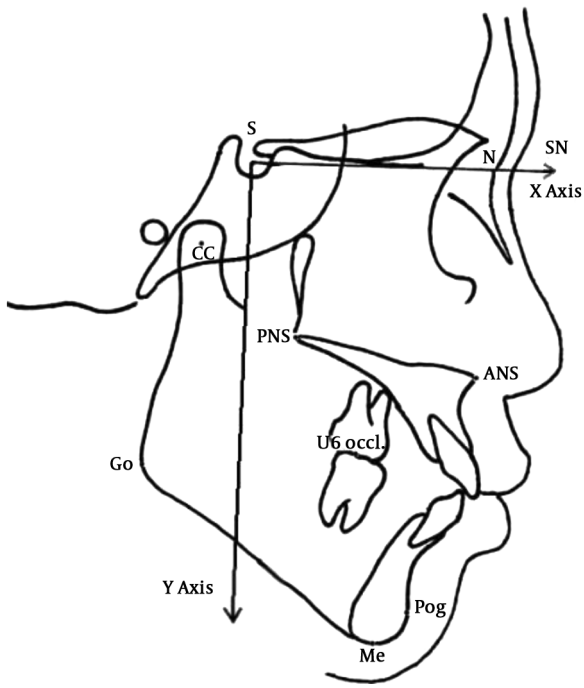

Figure 1. X and Y axes determination

The researchers were supposed to measure any changes in the location of the landmarks relative to these X and Y axis. Any movement in anterior and upward direction was considered as positive and in the posterior or downward direction was considered as negative measurement.

At the first stage, inter-examiner and intra-examiner er-

ror was calculated in the way that 5 cephalograms were traced by both examiners separately and then compared with each-other. After one week one examiner repeated traced the same 5 cephalograms. The results were compared and did not showed any significant differences. (P = 0.89) The measurement error in both land mark identification and linear measurements were between 0.1 to 0.2 mm.

3.1. Maxillary Center of Rotation (MxCR)

Pre-surgical and post-surgical lateral cephalograms were superimposed using SN as the reference plane. Pre-surgical maxillary plane (ANS-PNS) and post-surgical maxillary plane (ANS'-PNS') was drawn. The intersection of these two lines was considered as the MxCR. (Figure 2) This point could be far from the cranio-facial structures.

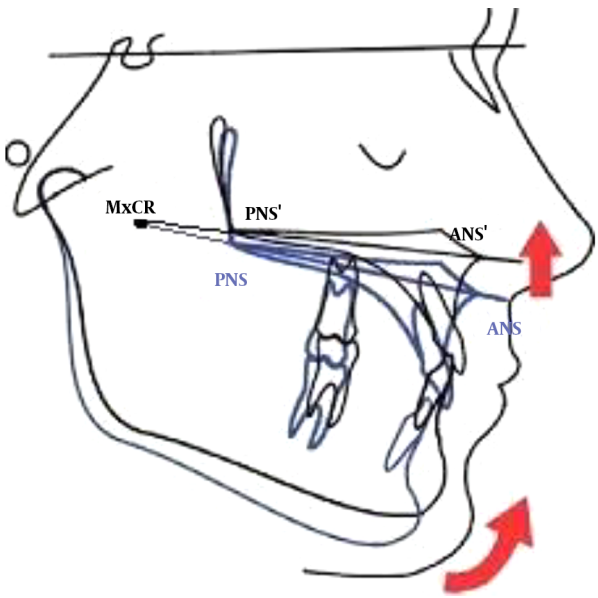

Figure 2. Maxillary center of rotation (MxCR): The intersection of pre-surgical maxillary plane (ANS-PNS) and post-surgical maxillary plane (ANS'-PNS').

3.2. Mandibular Center of Rotation (MnCR)

To determine the MnCR, the Reuleaux method was used (14) which was also applied in previous studies (6, 7). Point B and Go was considered as the reference landmarks. Post-surgical location of these landmarks was considered as B' and Go' respectively. The B-B' and Go-Go' landmarks was drawn and then the perpendicular bisector of B-B' and Go-Go' was drawn. The intersection of these perpendicular bisectors was considered as MnCR (Figure 3).

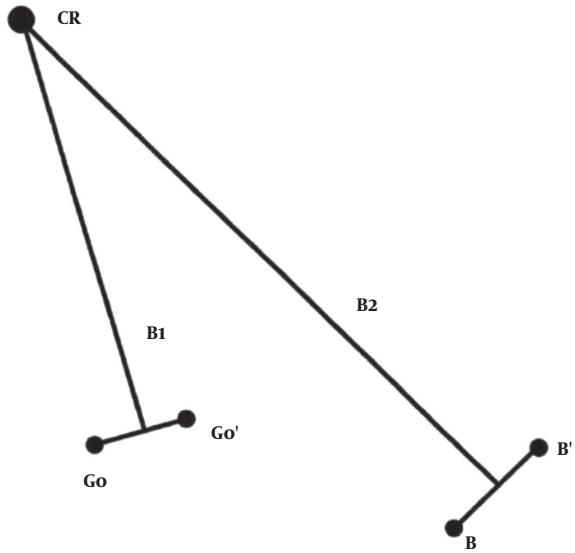

Figure 3. Determination the center of rotation of the mandible by the Reuleaux method. The location of perpendicular intersection of straight lines B-B' and Go-Go' is considered as the center of rotation of the mandible.

The coordinates of MnCR and MxCR relative to X and Y axis was measured in all cephalograms. The magnifications of radiographs were also calculated with the help of the image of the rulers in cephalograms.

Descriptive statistical analysis was performed to evaluate the mean distance of the MxCR and MnCR from the condylar center during maxillary impaction and mandibular setback or advancement. The correlation of the changes in the coordinates of MnCR and MxCR relative to X and Y axis was evaluated using Pearson correlations test. Statistical analysis was done by means of SPSS software (SPSS 25.0, IBM Corp, NY, USA).

To evaluate the type of the surgeries, the patients were also divided into subgroups according to type of mandibular surgery (advancement or setback) and type of maxillary impaction (anterior impaction, posterior impaction and parallel impaction) Pearson correlations test was also applied for subgroup analysis.

4. Results

The mean distance of MnCR to condylar center (CC) was 10.45 $\pm$ 6.35 cm with the minimum value of 3.60 cm and maximum value of 27.5 cm. The mean distance of MxCR to CC was 8.39 $\pm$ 5.42 cm with the minimum value of 1.45 cm and maximum value of 15.45 cm. As can be seen in Table 1, the correlation of X component of MnCR and MxCR

is positive but not statistically significant. (P = 0.357) The correlation of Y component of MnCR and MxCR is negative but not statistically significant (P = 0.441) (Table 2). The distance of CC to MnCR had a positive but insignificant correlation with the distance of CC to MxCR (Table 3).

Table 1. Correlation Coefficient of X-Component of Maxillary and Mandibular Centers of Rotation in 24 Patients

	MxCRX	MnCRX
MxCRX		
Pearson correlation coefficient	1	0.197
P value		0.357
Number of patients	24	24
MnCRX		
Pearson correlation coefficient	0.197	1
P value	0.357	
Number of patients	24	24

Abbreviations: MnCRX, X component of center of rotation of mandible; MxCRX, X component of center of rotation of maxilla.

Table 2. Correlation Coefficient of Y-Component of Maxillary and Mandibular Centers of Rotation in 24 Patients

	MxCRY	MnCRY
MxCRY		
Pearson correlation coefficient	1	-0.165
P value		0.441
Number of patients	24	24
MnCRY		
Pearson correlation coefficient	-0.165	1
P value	0.441	
Number of patients	24	24

Abbreviations: MnCRY, Y component of center of rotation of mandible; MxCRY, Y component of center of rotation of maxilla.

Regarding the type of mandibular surgery, the mean distance of CC to MnCR in mandibular setback was 10.4 cm. However, when the patients were distributed according to maxillary surgery, this distance was 7.9 cm in anterior impaction, 13.9 cm in posterior impaction and 11.02 cm in parallel impaction. In none of the subgroups, there were any correlation between the type of impaction and the relative mandibular center of rotation.

5. Discussion

Considering the importance of an accurate method of cephalometric prediction for achieving the best outcome of a surgery, this study was conducted on 24 patients which

Table 3. The Correlation Coefficient of the Distance of the Condyle Center to the Mandibular Center of Rotation and the Distance of the Condyle Center to the Maxillary Center of Rotation.

	cMnd	cMx
cMnd		
Pearson correlation coefficient	1	0.122
P value		0.571
Number of patients	24	24
cMx		
Pearson correlation coefficient	0.122	1
P value	0.571	
Number of patients	24	24

Abbreviations: cMnd, the distance of the center of rotation of the mandible to the center of the condyle; cMx, the distance of the center of rotation of the maxilla to the center of the condyle.

were treated by maxillary impaction with either mandibular setback or advancement. The location of maxilla and mandible's center of rotation was determined by means of Reuleaux (14) and its distance from condylar center was also evaluated.

The results of the study demonstrated that in no cases the MnCR was located on the condyle. The rotational direction of mandibular proximal segment (in the region of Go) and distal segment (in the region of B point) had high variety among the patients. However, in most cases of posterior maxillary impaction with mandibular setback, mandible had rotated upward and backward in B and Go region. Moreover, in cases of parallel maxillary impaction with mandibular setback, mandible had an upward and backward rotation in B point with a total counter-clockwise rotation. In cases of posterior maxillary impaction with mandibular setback, the direction of rotation was mostly upward and forward in B point and only forward in Go.

In most of mandibular advancement cases (combined with maxillary impaction), generally Go moved downward and B moved upward and forward, albeit some cases did not follow this pattern. Due to lack of sufficient samples in these subgroups, statistical analysis was not performed. No correlation was determined between the type of impaction and the relative mandibular center of rotation in any surgical groups.

In the previous studies there were significant variation in the location of MnCR. Sperry et al. evaluated the center of rotation of mandible (MnCR) during its autorotation following maxillary impaction in 23 patients. In the mastoid region, they found it to be 32 mm posterior in X axis and 28 mm inferior in Y axis of condylar center. Thus they reported a significant difference between condy-

lar and mastoidal center of rotation which caused a difference in prediction of landmarks in horizontal dimension (7). In a similar study by Nattestad et al. on 10 patients the MnCR was 8.4 mm posterior and 25.1 mm inferior to condylar CR and showed that an error of 2 mm in the location of CR would cause a 3-mm error in the final positioning of maxilla (11). Wang et al. also reported the MnCR to be 2.5 mm posterior and 19.6 mm inferior to condylar CR in 10 patient (10). In another study by Kim et al. on patients who had nonsurgical correction of their anterior open bite via maxillary molar intrusion, the center of mandibular autorotation was also located behind and below condylion but with individual variations (15). Bryan evaluated the validity of the three reference points recommended by Sperry as the CR of mandibular auto-rotation in 15 patients. These points included condylar hinge axis, condylion and mastoid point. They reported same validity for these landmarks (9).

In most studies, the MnCR in mono-max maxillary surgery was considered to be in condylar region. In the prediction of bi-max surgeries, after maxillary impaction, mandible is firstly rotated around condylar axis and then is advanced or setback without rotation. However, recently it is observed that the mandible MnCR is not coincident with condylar center and even it was not located in the places recommended by other studies (7, 10-12). Accordingly, it can be assumed that during mandibular advancement and setback, there would be some rotations which was not considered in predictions. The following can be considered as attributed factors: (1) Inter-personal variations in maxilla and mandible geometry; (2) The incision line in the mandible during osteotomy which makes the proximal and distal segments separated; (3) The rotations made by the surgeons during surgical procedure; (4) The amount of overjet and overbite prior to surgery; (5) the amount of impaction and the treatment plan for the location of maxillary CR; (6) occlusal plane inclination; (7) patient's occlusion; (8) The fabricated surgical splints.

In the current study, to evaluate the distance of CR of jaws from condylar CR, a line was drawn from condylar CR to both MnCR and MxCR and the correlation of these measurements were tested. The results demonstrated a negative correlation between palatal plane and S-N plane. (relative to Y axis) and the distance between MnCR and S-N. It means that as the distance between MxCR and S-N decrease the distance between MnCR and S-N increase and it located more downward. Thus, in patients with parallel maxillary impaction, as the palatal plane moves upward, the MnCR locates more downward. Moreover, when the MxCR in horizontal axis (X-axis) is closer to ANS, the MnCR is also located more anteriorly with a positive but insignificant correlation. The results demonstrated that the amount of maxillary impaction, and the location of MxCR affects the location of MnCR.

It is recommended to conduct a prospective study, with more controlled condition and also with computerized prediction. However, due to several interfering factor, it would be difficult to gather enough samples.

5.1. Conclusions

The location of MnCR in bimaxillay surgeries, was not in condylar region and had a high interpersonal variation. As the MxCR got closer to ANS, MnCR moved anteriorly with a positive but insignificant correlation.

The less the distance between MxCR and SN line was, the less the distance between MnCR and SN and the upper the location of MnCR was.

When the distance between MxCR and condyle increased, it also increased for MnCR.

In most cases when the horizontal component of B point movement was large, the distance of MnCR with condylar CR increased in vertical dimension.

The direction of mandibular proximal segment (in Go point) and distal segment (in B point) had a high variation in the study cases.

Footnotes

Authors' Contribution: Delaram Shahbodaghi: acquisition of data; Tahereh Hosseinzadeh Nik: study concept and design, analysis and interpretation of data; Mohammad Sadegh Ahmad Akhundi: administrative, technical, and material support; Shahab Kavoosinejad: drafting of the manuscript; Atefe Saffar Shahroudi: critical revision of the manuscript for important intellectual content

Conflict of Interests: The authors declare no conflict of interest.

Ethical Approval: This research was approved by the Ethics Committee of Tehran University of Medical Sciences.

Funding/Support: This research was a part of an MS thesis with the reference number of 6351 conducted in and funded by Dental School of Tehran University of Medical Sciences.

References

1. Proffit WR, White RP, Sarver DM. *Contemporary treatment of dentofacial deformity*. **283**. Mosby St. Louis; 2003.
2. Kolokitha O, Chatzistavrou E. Factors influencing the accuracy of cephalometric prediction of soft tissue profile changes following orthognathic surgery. *Journal of maxillofacial and oral surgery*. 2012;**11**(1):82-90.
3. Fish LC, Epker BN. Surgical-orthodontic cephalometric prediction tracing. *Journal of clinical orthodontics: JCO*. 1980;**14**(1):36.

4. Abuzinada S, Alsulaimani F. Mandibular changes associated with maxillary impaction and molar intrusion. *Open Journal of Stomatology*. 2013;**3**(9):515–9.
5. Rekow ED, Speidel TM, Koenig RA. Location of the mandibular center of autorotation in maxillary impaction surgery. *American Journal of Orthodontics and Dentofacial Orthopedics*. 1993;**103**(6):530–6.
6. Peleg O, Mijiritsky E, Manor Y, Inchingolo F, Blinder D, Mortellaro C, et al. Predictability of Mandibular Autorotation After Le Fort I Maxillary Impaction in Case of Vertical Maxillary Excess. *Journal of Craniofacial Surgery*. 2019;**30**(4):1102–4.
7. Sperry TP, Steinberg MJ, Gans BJ. Mandibular movement during autorotation as a result of maxillary impaction surgery. *American Journal of Orthodontics and Dentofacial Orthopedics*. 1982;**81**(2):116–23.
8. Nattestad A, Vedtofte P, Mosekilde E. The significance of an erroneous recording of the centre of mandibular rotation in orthognathic surgery. *Journal of Cranio-Maxillofacial Surgery*. 1991;**19**(6):254–9.
9. Bryan DC. An investigation into the accuracy and validity of three points used in the assessment of autorotation in orthognathic surgery. *British journal of oral and maxillofacial surgery*. 1994;**32**(6):363–72.
10. Wang Y, Ko EW, Huang C, Chen Y. The inter-relationship between mandibular autorotation and maxillary LeFort I impaction osteotomies. *Journal of Craniofacial Surgery*. 2006;**17**(5):898–904.
11. Nattestad A, Vedtofte P. Mandibular autorotation in orthognathic surgery: a new method of locating the centre of mandibular rotation and determining its consequence in orthognathic surgery. *Journal of cranio-maxillofacial surgery*. 1992;**20**(4):163–70.
12. Nadjmi N, Mommaerts MY, Abeloos JV, De Clercq CA. Prediction of mandibular autorotation. *Journal of oral and maxillofacial surgery*. 1998;**56**(11):1241–7.
13. Gimenez CMM, Bertoz FA, Gabrielli MAC, Magro Filho O, Garcia I, Pereira Filho VA. Cephalometric evaluation of the predictability of bimaxillary surgical-orthodontic treatment outcomes in long face pattern patients: a retrospective study. *Dental press journal of orthodontics*. 2013;**18**(5):53–8.
14. Reuleaux F. *The kinematics of machinery: outlines of a theory of machines*. Courier Corporation; 2013.
15. Kim K, Choy K, Park Y, Han SY, Jung H, Choi YJ. Prediction of mandibular movement and its center of rotation for nonsurgical correction of anterior open bite via maxillary molar intrusion. *The Angle Orthodontist*. 2018;**88**(5):538–44.