



Qualitative Description of the Effects of Rapid Maxillary Expansion: A Three-Dimensional Perspective

Luis Huanca Ghislanzoni,^{1*} Roberta Lione,² Lorenzo Franchi,³ and Paola Cozza⁴

¹Research Assistant, Department of Orthodontics, University of Geneva, Switzerland and Private Practice in Albino (Italy) and Lausanne (Switzerland)

²Research Assistant, Department of Orthodontics, University of Rome Tor Vergata, Italy and Department of Dentistry UNSBC, Tirana

³Assistant Professor, Department of Surgery and Translational Medicine, University of Florence, Florence, Italy

⁴Professor and Head, Department of Orthodontics, University of Rome Tor Vergata, Italy. Head of the Department of Dentistry UNSBC Tirana

*Corresponding author: Luis Huanca Ghislanzoni, Chemin Porchat 22, 1004 Lausanne (VD), Switzerland. Tel: +39-3490088719, E-mail: dottor.acca@gmail.com

Received 2016 July 10; Accepted 2016 September 14.

Abstract

Background: The effects of rapid maxillary expansion (RME) have been widely studied with classic bidimensional imaging.

Objectives: The study aimed to determine immediate post-expansion effect of RME with three-dimensional imaging.

Methods: Computed tomography (CT) low dose scan records were taken for three patients before applying RME (T0), and immediately after the end of the active expansion phase (T1). For one patient a CT scan was available also at T2, at time of RME removal. Image analysis was done in 4 steps: segmentation of the face skull, model construction and exportation of .stl surface shells, cranial base superimpositions and colorimetric maps overlay.

Results: There were differences in the bone adaptations to RME, but it was possible to identify some common trends in the three patients. All of the three patients showed a pattern of forward movement of the maxilla associated to the suture opening. Patients 1 and 3 demonstrated also a downward movement of the maxilla, which was not visible on patient 2. As a sagittal advancement of almost 6 mm, as visible in patients 1 and 3, was not possible due to growth in only two weeks, all bony changes could be attributed to the RME. For patient 1, the bony changes present at T1, were still present at T2, while the suture was closed.

Conclusions: A pattern of forward immediate displacement of the maxilla with respect to the cranial base was consistently noticed in three patients. The vomer bone maintained a connection with one half of the maxilla when the suture opened.

Keywords: Rapid Maxillary Expansion, Three-Dimensional Imaging, Computed Tomography

1. Background

The effects of rapid maxillary expansion (RME) have been widely studied and sometimes criticized (1-4). Some Authors focused on side effects of the RME both on the vertical plane (5-8) and on the sagittal plane (6-9), as seen from lateral cephalograms. As the aim of the expander is to increase the transversal dimensions, there were claims for clockwise rotation of the mandible as a consequence of increased vertical dimension of the maxilla in the short term (5-8). A recent long-term study showed that RME can be carried out successfully in patients with increased vertical dimensions without detrimental effects on the vertical skeletal relationships (10). An immediate sagittal forward projection of the maxilla was also assessed (6-9).

Studies on the short-term effects of RME from a bidimensional perspective lost clinical interest at least a decade ago. The advent of cone-beam computed tomography (CBCT) lead to a new and more comprehensive way to look at treatment outcomes. Cevitanes et al. defined a

method for superimposition on the cranial base for CBCT images that allows to analyze skeletal changes in three-dimensions (3D) (11, 12). Magnusson et al. (13) applied the method of volumes superimposition to study skeletal transversal changes in adults receiving a surgically assisted rapid palatal expansion (13). More recently Gkantidis et al. (14) described and tested the reproducibility of a method of superimpositions on the cranial base of surfaces extracted from CBCT data (14).

The aim of this study was to apply the 3D superimposition method on the cranial base of three growing patients undergoing a RME treatment in order to analyze the skeletal changes that occurred in the maxillary region.

2. Methods

From a sample of 17 patients (15, 16) who were treated with a banded RME (17) at University of Rome "Tor Vergata", 3 prepubertal patients were selected for having the cranial

base fully visible into the 13.7×13.7 field of view of the low-dose CT scan. The age of the three subjects was 8.9, 10.1 and 12.0 years. All the patients presented with constricted maxillary arches, variable degree of crowding and one or both displaced maxillary canines as assessed by panoramic radiograph. The treatment protocol consisted of two turns per day (0.4 mm) for two weeks (7 mm) until overcorrection of the transverse width was achieved (palatal cusp of the upper posterior teeth approximating the buccal cusp of the lower posterior teeth). After the active phase of expansion the appliance was left in place six months to allow for the complete ossification of the midpalatal suture (15).

Computed tomography (CT) low dose scans of the 3 subjects were available at 2 time points: immediately before appliance placement (T0), at the end of active expansion (T1). Low-dose CT scans were taken with a scanner console (Light-Speed 16, General Electric Medical System, Milwaukee, Wisconsin, USA) with a 1.25 mm slice thickness, 13.7×13.7 cm field of view (FOV), following a low dose protocol with 80 KV instead of the standard setting used for a Dentascan of 120 KV (16).

Image analysis was done in 4 steps: segmentation of the face skull, model construction and exportation of .stl surface shells (11, 12) (with ITK-Snap open-source software, www.itksnap.org), cranial base superimpositions (13) and colorimetric maps overlay (with VAM software, Canfield Scientific, Fairfield, New Jersey, USA).

The study was done under the approval of the local ethical committee (15, 16).

3. Results

The color code for standard superimposition (no color distance algorithm applied) is the following: orange T0, purple T1.

When performing color map superimposition a colorimetric scale is presented at the side of each figure: the darker the blue the bigger/outer the superimposed shell, with regard to the reference. Green stays for no changes and red stays for a restrain in dimensions. The limits of the scale are shown at the edges of the scale, and the scale was set as going from -6mm (red), to +6mm (blue), passing from 0 (green, no linear differences between the surfaces).

There were some differences in the bone adaptations to RME, but it was possible to identify some common trends in the three patients.

All of the three patients showed a pattern of forward movement of the maxilla associated to the suture opening (Figure 1). Forward movement was marked in patient 1 and 3, and smaller in patient 2.

Patients 1 and 3 demonstrated also a downward movement of the maxilla, which was not visible on patient 2 (Figure 2).

The distance color map images showed that changes were concentrated and maximal at the dental level and at the alveolar process area of the maxilla. They involved also the malar region (outer wall of maxillary sinus) and they extended up to the zygomatic process of the maxilla, as it's visible in patients 1 and 3. In patient 2, asymmetrical changes were concentrated in the right alveolar process and malar region of the right hemi-maxilla (Figures 3 - 5).

The vomer bone maintained a connection with one side of the hemi-maxilla. In patient 2 it was possible to notice a marked asymmetry in suture opening, with one of the halves staying "locked" and the other half responding asymmetrically to the screw opening (Figures 1,4).

As a sagittal advancement of almost 6 mm, as visible in patients 1 and 3 (Figure 1), was not possible due to growth in only two weeks (time of activation of the screw), all bony changes could be attributed to the RME protocol. Some Authors identified an advancement of point A, and mandibular post-rotation. While it is difficult to them them out from classic 2D radiographs, this phenomenon may be easier interpreted with the help of 3D imaging. In fact, it seems that, in order to separate at the level of the midpalatal suture, the two halves of the maxilla need to "squeeze" out through forward and downward (Figure 6). This is very likely to be the only way to win the resistance of the posterior circum-maxillary sutures. The classical V-shaped opening of the suture that was recorded with occlusal radiographs, is apparently possible due to a displacement of each hemi-maxilla towards a zone of no resistance, i.e. forward and downward, as circum-maxillary sutures are mainly located in the posterior and upper zone of the maxilla.

For Patient 1, a CT including the cranial base was available at T2, immediately after appliance removal (Figure 7). When superimposing T2 on T1, it was possible to notice only minor changes, while the suture appeared to be closed due to re-ossification. The superimposition of T2 and T0 showed a sagittal forward movement of the same entity as the one recorded at T1. While closing at the level of the suture, it seems that the maxillary bones were able to keep the changes induced by the RME.

A limit of this study is the limited number of patients observed. However, it's hard to extensively increase the number of observations due to ethical reasons. It was at least possible to observe with a 3D perspective the effect of suture opening due to rapid maxillary expander and try to better interpret some of the consequences recognized by Authors studying maxillary expansion.

Individual variability seems to play a main role and

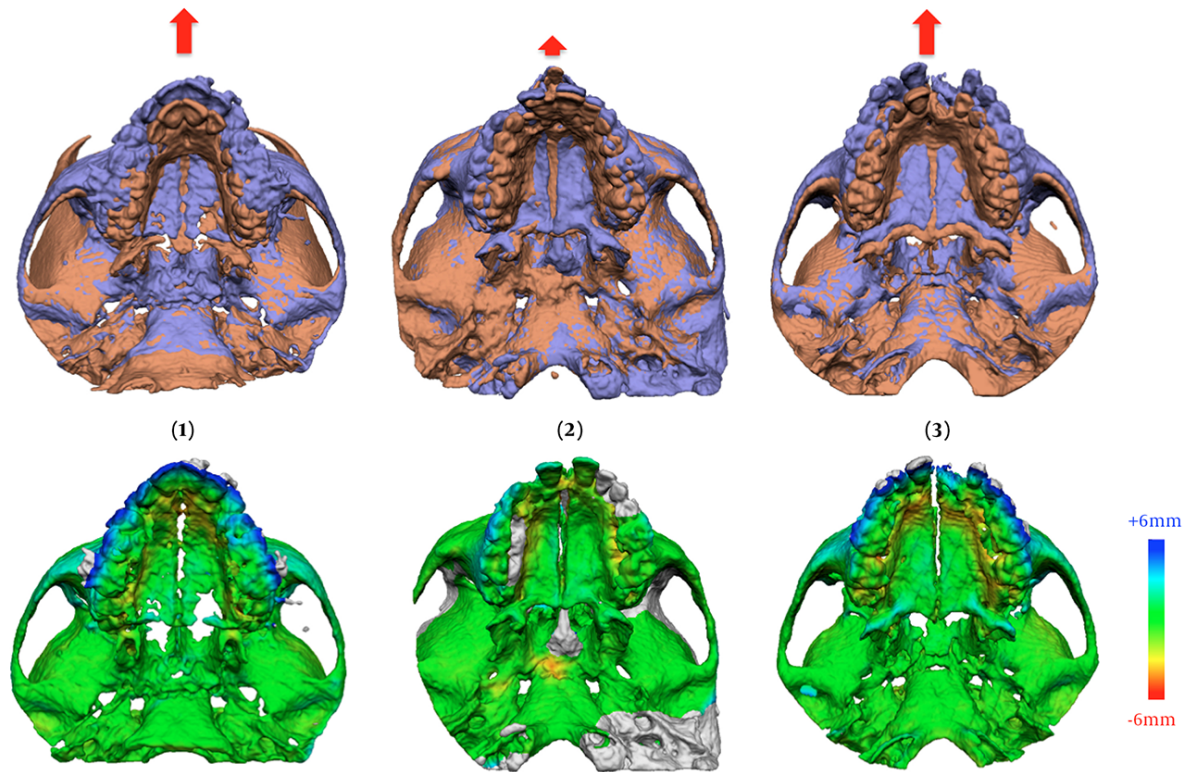


Figure 1. All of the Three RME Patients Showed a Pattern of Forward Movement of the Maxilla Associated to the Suture Opening

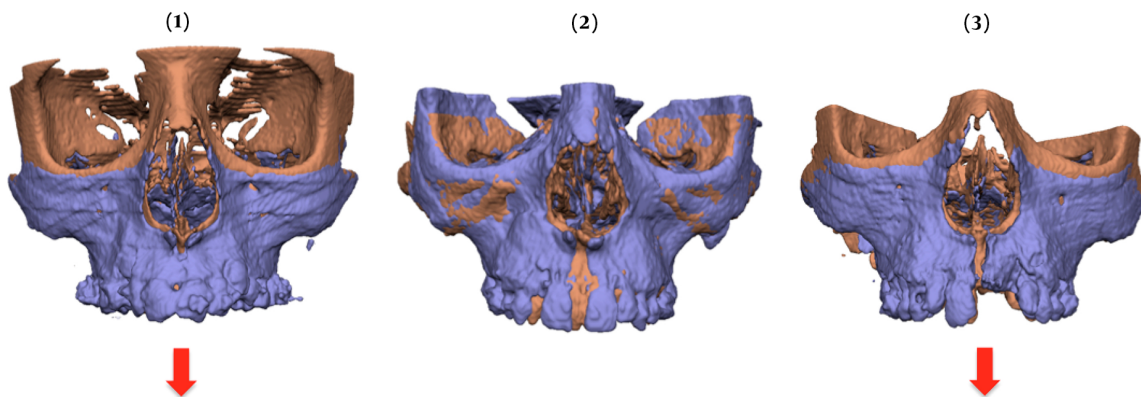


Figure 2. Patients 1 and 3 demonstrated Also a Downward Movement of the Maxilla, Which Was Not Visible on Patient 2

other observations are needed to assess what happens to the maxilla when using an RME.

4. Conclusions

The present study is a qualitative representation of what happened in a 3D perspective to the maxilla when a RME appliance was used.

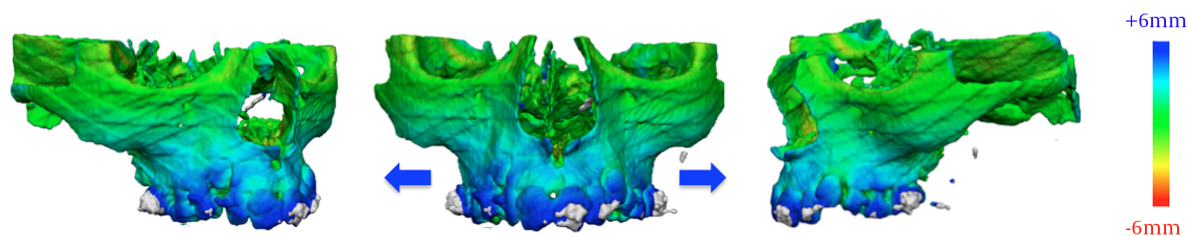


Figure 3. Color Maps Changes for Patient 1

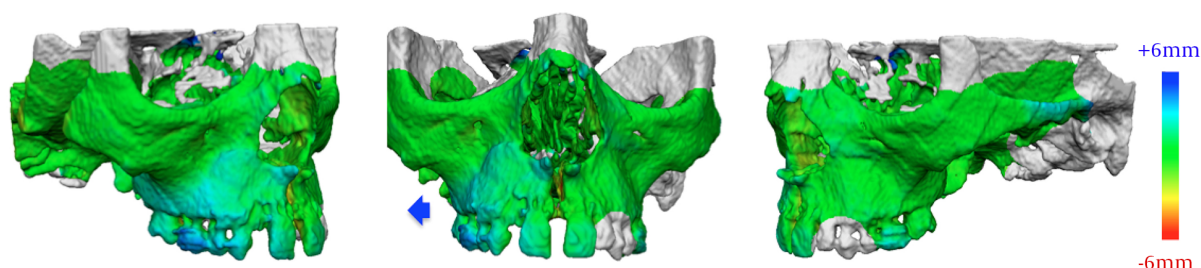


Figure 4. Color Maps Changes for Patient 2 with Asymmetric Suture Opening

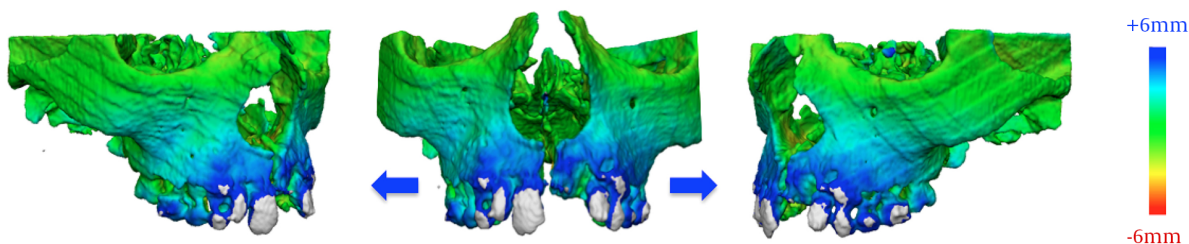


Figure 5. Color Maps Changes for Patient 3

A pattern of forward immediate displacement of the maxilla with respect to the cranial base was consistently noticed in three patients. The vomer bone maintained a connection with one half of the maxilla when the suture opened

References

1. Bishara SE, Staley RN. Maxillary expansion: Clinical implications. *American Journal of Orthodontics and Dentofacial Orthopedics*. 1987;**91**(1):3-14. doi: [10.1016/0889-5406\(87\)90202-2](https://doi.org/10.1016/0889-5406(87)90202-2).
2. Lagravere MO, Major PW, Flores-Mir C. Long-term skeletal changes with rapid maxillary expansion: a systematic review. *Angle Orthod*. 2005;**75**(6):1046-52. doi: [10.1043/0003-3219\(2005\)75\[1046:LSCWRM\]2.0.CO;2](https://doi.org/10.1043/0003-3219(2005)75[1046:LSCWRM]2.0.CO;2). [PubMed: 16448254].
3. Fotovatjah M. *Stability of rapid maxillary expansion*. 1993.
4. Wertz R, Dreskin M. Midpalatal suture opening: A normative study. *Am J Orthod Orthop*. 1977;**71**(4):367-81. doi: [10.1016/0002-9416\(77\)90241-X](https://doi.org/10.1016/0002-9416(77)90241-X).
5. Gabriel de Silva Fo O, Boas CV, Capelloza LFO. Rapid maxillary expansion in the primary and mixed dentitions: A cephalometric evaluation. *Am J Orthod Dentofacial Orthop*. 1991;**100**(2):171-9. doi: [10.1016/S0889-5406\(05\)81524-0](https://doi.org/10.1016/S0889-5406(05)81524-0).
6. Akkaya S, Lorenzon S, Ucem TT. A comparison of sagittal and vertical effects between bonded rapid and slow maxillary expansion procedures. *Eur J Orthod*. 1999;**21**(2):175-80. doi: [10.1093/ejo/21.2.175](https://doi.org/10.1093/ejo/21.2.175). [PubMed: 10327741].
7. Sari Z, Uysal T, Usumez S, Basciftci FA. Rapid maxillary expansion. Is it better in the mixed or in the permanent dentition?. *Angle Orthod*. 2003;**73**(6):654-61. doi: [10.1043/0003-3219\(2003\)073\[0654:RMEIIBgt;2.0.CO;2](https://doi.org/10.1043/0003-3219(2003)073[0654:RMEIIBgt;2.0.CO;2). [PubMed: 14719729].

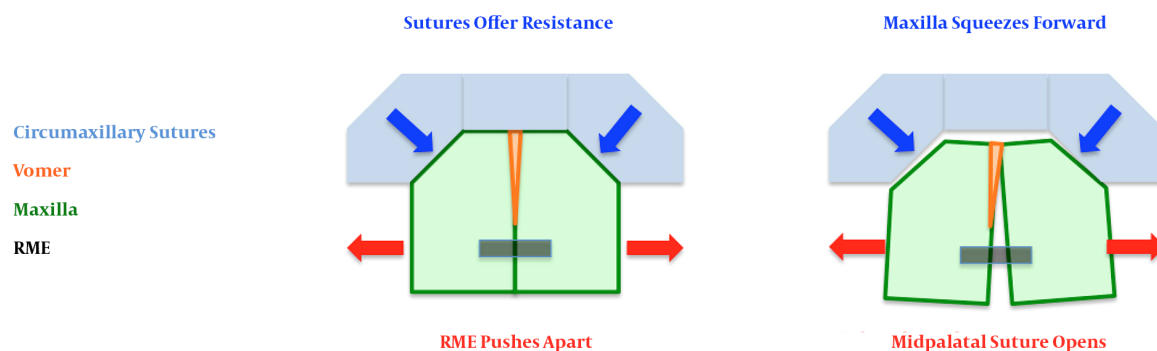


Figure 6. In Order to Separate At the Level of the Midpalatal Suture, the Two Halves of the Maxilla Need to “Squeeze” out Through Forward and Downward

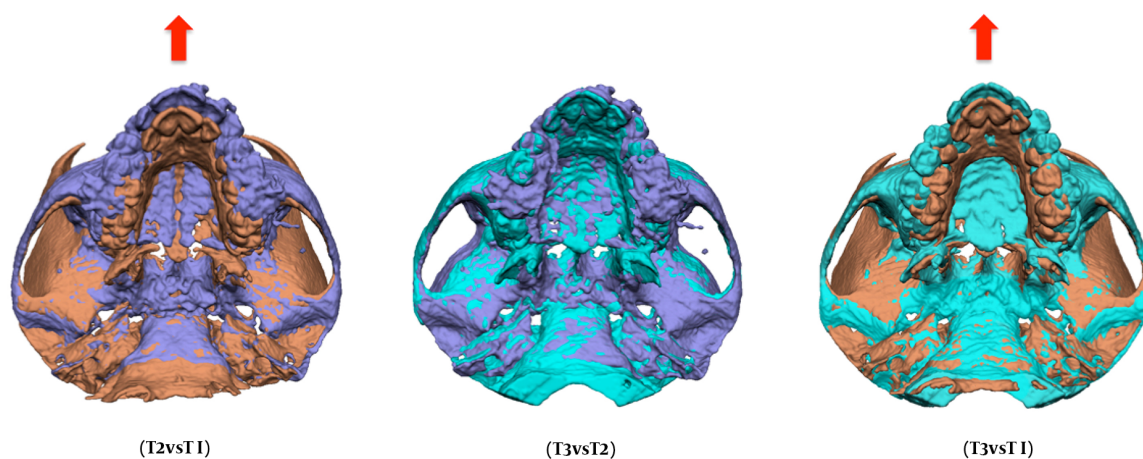


Figure 7. For Patient 1, a CT Including the Cranial Base Was Available at T2, Immediately After Appliance Removal

8. Chung CH, Font B. Skeletal and dental changes in the sagittal, vertical, and transverse dimensions after rapid palatal expansion. *Am J Orthod Dentofacial Orthop.* 2004;**126**(5):569-75. doi: [10.1016/j.ajodo.2003.10.035](https://doi.org/10.1016/j.ajodo.2003.10.035).
9. Haas AJ. Rapid expansion of the maxillary dental arch and nasal cavity by opening the midpalatal suture. *Angle Orthod.* 1961;**31**(2):73-90.
10. Lineberger MW, McNamara JA, Baccetti T, Herberger T, Franchi L. Effects of rapid maxillary expansion in hyperdivergent patients. *Am J Orthod Dentofacial Orthop.* 2012;**142**(1):60-9. doi: [10.1016/j.ajodo.2012.02.019](https://doi.org/10.1016/j.ajodo.2012.02.019). [PubMed: 22748991].
11. Cevidanes LH, Heymann G, Cornelis MA, DeClerck HJ, Tulloch JF. Superimposition of 3-dimensional cone-beam computed tomography models of growing patients. *Am J Orthod Dentofacial Orthop.* 2009;**136**(1):94-9. doi: [10.1016/j.ajodo.2009.01.018](https://doi.org/10.1016/j.ajodo.2009.01.018). [PubMed: 19577154].
12. Cevidanes LH, Bailey LJ, Tucker GJ, Styner MA, Mol A, Phillips CL, et al. Superimposition of 3D cone-beam CT models of orthognathic surgery patients. *Dentomaxillofac Radiol.* 2005;**34**(6):369-75. doi: [10.1259/dmfr/17102411](https://doi.org/10.1259/dmfr/17102411). [PubMed: 16227481].
13. Magnusson A, Bjerklín K, Kim H, Nilsson P, Marcusson A. Three-dimensional assessment of transverse skeletal changes after surgically assisted rapid maxillary expansion and orthodontic treatment: a prospective computerized tomography study. *Am J Orthod Dentofacial Orthop.* 2012;**142**(6):825-33. doi: [10.1016/j.ajodo.2012.08.015](https://doi.org/10.1016/j.ajodo.2012.08.015). [PubMed: 23195368].
14. Gkantidis N, Schauseil M, Pazera P, Zorkun B, Katsaros C, Ludwig B. Evaluation of 3-dimensional superimposition techniques on various skeletal structures of the head using surface models. *PLoS One.* 2015;**10**(2). e0118810. doi: [10.1371/journal.pone.0118810](https://doi.org/10.1371/journal.pone.0118810). [PubMed: 25706151].
15. Lione R, Ballanti F, Franchi L, Baccetti T, Cozza P. Treatment and posttreatment skeletal effects of rapid maxillary expansion studied with low-dose computed tomography in growing subjects. *Am J Orthod Dentofacial Orthop.* 2008;**134**(3):389-92. doi: [10.1016/j.ajodo.2008.05.011](https://doi.org/10.1016/j.ajodo.2008.05.011). [PubMed: 18774085].
16. Ballanti F, Lione R, Fiaschetti V, Fanucci E, Cozza P. Low-dose CT protocol for orthodontic diagnosis. *Eur J Paediatr Dent.* 2008;**9**(2):65-70. [PubMed: 18605887].

17. Cozza P, Giancotti A, Petrosino A. Rapid palatal expansion in mixed dentition using a modified expander: a cephalometric investigation. *J Orthod*. 2001;**28**(2):129-34. doi: [10.1093/ortho/28.2.129](https://doi.org/10.1093/ortho/28.2.129). [PubMed: [11395527](https://pubmed.ncbi.nlm.nih.gov/11395527/)].